

## **Homeopathic perspective in treating a case of Barrett's esophagus**

**Gavhane (PG Scholar part II)**

### **Abstract**

Barrett's esophagus is a complication of the gastro esophageal reflux disease. Gastro esophageal Reflux Disease (GERD) in which stomach acids are refluxed up through the esophagus and oral cavity, causing heartburn, chest pain, hoarseness, asthma, recurrent pneumonia, chronic cough, reflux laryngitis, and sore throat, and has different signs and symptom depending on the severity of the disease. Barrett's esophagus is a pre-malignant condition that is diagnosed by endoscopy and biopsy. The current case report is about a 38-year-old female who was diagnosed with GERD resulting in Barrett's esophagus. In this article, I given an account on this disease and cited a case treated homeopathically.

**Keywords:** Adenocarcinoma, Barrett's esophagus, GERD, heartburn, homoeopathy, Arsenicum album, Abies nigra, Chelidonium.

### **Introduction:**

Barrett's esophagus is a premalignant condition in which the normal squamous lining of the lower esophagus is replaced by columnar mucosa (columnar lined esophagus; CLO) containing areas of intestinal metaplasia<sup>(1)</sup>.

Barrett's esophagus is a serious complication of GERD (Gastro esophageal Reflux Disease) which is a disorder wherein the stomach contents leak from the stomach back into the esophagus leading to a symptom syndrome that includes heartburn, pain or discomfort in the chest, difficulty in swallowing, burning sensation in the esophagus, sore throat, chronic cough, nausea after eating, belching, bad breath, reflux-related sleep disorders, yellow fluid or stains on pillow.

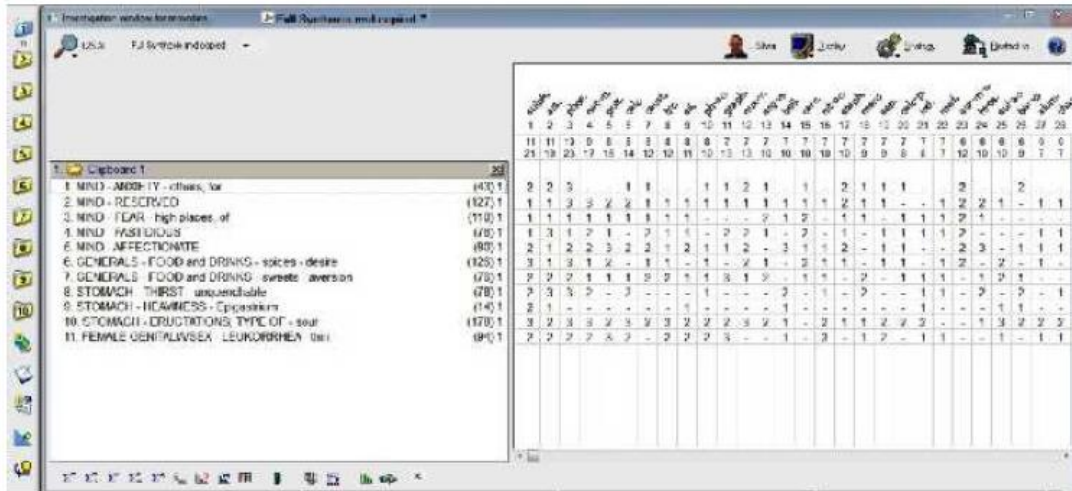
About 10% of people with chronic symptoms of GERD develop Barrett's esophagus. The Cause of Barrett's esophagus is thought to be an adaptation to chronic acid exposure from reflux esophagitis<sup>(2)</sup>. Community based epidemiological and autopsy studies suggest the true prevalence may be up to 20 times greater, as the condition is often asymptomatic until first discovered when the patient presents with esophageal cancer. CLO is a major risk factor for esophageal adenocarcinoma, with a lifetime cancer risk of around 10%. The absolute risk is low, however, and more than 95% of patients with CLO die from causes other than esophageal cancer. The prevalence is increasing, and it is more common in men (especially white) and those over 50 years of age.

In terms of gender, studies from Asian countries showed that men are more likely to have Barrett's esophagus with a male/female ratio of approximately 1.93–2.09. The prevalence of Barrett's esophagus is reportedly as high as 19.9% in Japan and 23.6% in India. While the prevalence of BE in Asia outside Japan and India ranges from 0.06% to 6%<sup>(3)</sup>.

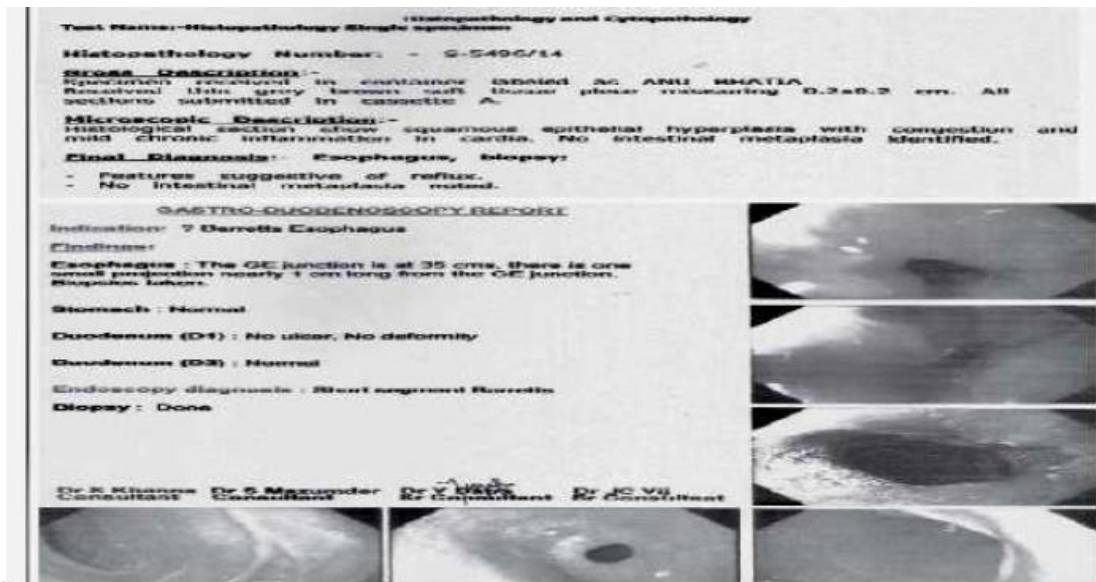Its malignant sequel, esophago gastric-junctional adenocarcinoma, has a mortality rate of over 85%<sup>(4)</sup>. The risk of developing esophageal adenocarcinoma in people who have Barrett's esophagus has been estimated to be 6–7 per 1000 person-years. Diagnosis requires multiple systematic biopsies to maximize



Repertorization was done using RADAR Version 10.5.003 schroyens F.,Synthesis 9.0(English)



Repertorial Result : Sulph.21/11, Ars.alb.19/11, Phos. 23/10, Nat.mur. 17/9 , Puls. 15/8.



**Inference**

The patient was in a state of anxiety about her condition. After taking her case she was reassured and the symptomatic remedy was given on the first visit, *Abies nigra* 30 that helped her and she gained confidence in the homoeopathic system. Thereafter, the case was thoroughly analyzed and repertorized. Her constitutional remedy came out to be *Arsenicum album* that was given in LM potency in varying from 0/1 to 0/8, seeing the gravity of the pathological changes in this case. This remedy was almost continued in the LM potency throughout the case. *Chelidonium*, a related organ remedy (but not prescribed) to Arsenic was selected as there had been a family history of cirrhosis of liver in father, also there had been symptoms in favor of this organ remedy (Allen’s Encyclopaedia:<sup>(8)</sup> ‘Extremely depressed; full of sad thoughts about the present and future, even to weeping; he had no rest of any kind, Eructation with heartburn and great weariness, Stool softer than usual in the morning ;in the afternoon soft stool, with

urging'). *Tuberculinum* LM was intercurrently used for the strong tubercular base. Over all in a span of 8 months the patient was markedly improved, about 80%, and is still under observation.

**Homoeopathic Perspective:**

Barrett's esophagus is one of complication of chronic GERD that can lead to adenocarcinoma of esophagus. Homoeopathy believes in treating the man in disease and not the disease in man; so a proper understanding of the patient with the suffering is evaluated in terms of anamnesis, his habits, lifestyle, the *causa occasionalis* and the underlying miasm. Homoeopathic medicines work to relieve the symptoms of gastro esophageal reflux disease by initiating the body's innate response to a stimulus or to an irritation allowing the body to heal itself. Homeopathy offers a selection of remedies to relieve symptoms of acid reflux and GERD that may act as precursor of Barrett esophagus or CA esophagus. <sup>(10)</sup>

**Conclusion:**

Homoeopathy deals with the patients holistically and considers the linear and non-linear causes as well. In cases where the cause is not known, the homoeopathic physician may go into the depth of the case by reviewing the thorough life space of the individual and base his prescription on those unidentifiable (non-linear) causes. As GERD/Barrett's esophagus needs a long term monitoring of the case, along with the best selected medicines based on individualized symptoms, he can modify the lifestyle of the patient by advising him/her proper diet and regimen to be followed to check the progression of disease in time primarily and getting cured in the long run. This case is an example of this where the well framed plan of homoeopathic treatment brought out the patient from her chronic symptoms beautifully.

**Reference**

- 1) Davidson's Principles and Practice of Medicine, 21st Edition, diseases of the esophagus, page no. 863-867.
- 2) Stein HJ, Siewert JR (1993). "Barrett's esophagus: pathogenesis, epidemiology, functional abnormalities, malignant degeneration, and surgical management". *Dysphagia* : page no. 276-88
- 3) [http://www.medscape.com/viewarticle/740026\\_2](http://www.medscape.com/viewarticle/740026_2).
- 4) Holmes RS, Vaughan TL (January 2007). "Epidemiology and pathogenesis of esophageal cancer". *Semin Radiat Oncol* 17 : page no. 2-9.
- 5) Barrett NR (October 1950). "Chronic peptic ulcer of the esophagus and 'esophagitis'". *Br J Surg* 38 (150): page no. 175-82.
- 6) Allison PR, Johnstone AS (June 1953). "The esophagus lined with gastric mucous membrane". *Thorax* 8(2): page no. 87-101.
- 7) RADAR Version 10.5.005 Schroyens F., Synthesis 9.0 (English).
- 8) Allen T. F., *Encyclopedia of Pure Materia Medica*. New Delhi: B Jain Publishers; 2009.
- 9) <http://www.drthindhomeopathy.com/diseases/barrett-syndrome-barrettesophagus>.
- 10) [http://www.naturalnews.com /028924\\_ GERD\\_homeopathic.html](http://www.naturalnews.com /028924_ GERD_homeopathic.html).
- 11) Boericke W. *New Manual of Homoeopathic Materia Medica with Repertory*. 3rd Revised and Augmented Ed. New Delhi: B Jain Publishers; 2010.