

Liver diseases diagnosed as Liver cirrhosis with Homoeopathic Treatment: A Case Report

Prof. Dr. Virendra Jain¹, Dr. Sheetal Kumawat², Dr. Pranjali Patil,

Prof. Homoeopathic Materia Medica and PG guide, Motiwala (National) Homoeopathic Medical College, Nashik

ABSTRACT: Liver diseases, including non-alcoholic fatty liver disease (NAFLD) and cirrhosis, are prevalent globally and can arise from various etiologies such as obesity, excessive alcohol consumption, hepatitis infections, autoimmune disorders, cholestatic conditions, and metabolic overloads of iron or copper. Liver cirrhosis, characterized by the formation of regenerative nodules surrounded by fibrous bands and progressive hepatic dysfunction, often leads to severe complications such as variceal bleeding, portal hypertension, and coagulopathy. Traditional management typically involves addressing these complications through conventional medical approaches. This case report presents the management of a patient with liver cirrhosis and its complications using a homeopathic treatment approach. By focusing on the totality of symptoms rather than isolated manifestations, homeopathic treatment aims to address the underlying imbalance and promote overall health. The report highlights the therapeutic process, patient response, and outcomes, providing insights into the potential role of homeopathy in managing complex liver cirrhosis cases.

KEYWORDS: Liver cirrhosis, Homoeopathic treatment

INTRODUCTION:

Liver cirrhosis is the final pathological result of chronic liver injury leading to histological development of regenerative nodules surrounded by fibrous bands ⁽¹⁾⁽²⁾⁽³⁾. Worldwide, the leading causes of liver cirrhosis are chronic viral hepatitis, excessive alcohol consumption for long period, and non-alcoholic fatty liver disease (NAFLD)⁽⁴⁾.

The etiology of cirrhosis ⁽³⁾⁽⁴⁾ :

Alcoholism: Chronic excessive alcohol consumption leads to liver damage through repeated cycles of inflammation and repair. Over time, this results in fibrosis and ultimately cirrhosis as the liver tissue becomes scarred and loses function.

Chronic Hepatitis C Virus Infection: Hepatitis C virus (HCV) causes persistent liver inflammation. Chronic infection triggers ongoing liver damage, fibrosis, and eventually cirrhosis. The virus disrupts normal liver function and promotes fibrous tissue formation.

Nonalcoholic Fatty Liver Disease (NAFLD): NAFLD is characterized by the accumulation of fat in the liver in individuals who consume little to no alcohol. This condition can progress from simple fatty liver to nonalcoholic steatohepatitis (NASH) and eventually to cirrhosis, driven by inflammation, oxidative stress, and insulin resistance.

Chronic Hepatitis B: This viral infection causes persistent liver inflammation, leading to progressive liver damage and fibrosis. Over time, the ongoing damage can result in cirrhosis.

Hemochromatosis: An inherited disorder causing excessive iron accumulation in the liver and other organs, leading to oxidative damage, fibrosis, and eventually cirrhosis.

Wilson's Disease: A genetic disorder resulting in copper buildup in the liver, causing cellular damage and inflammation that progress to cirrhosis if untreated.

Primary Biliary Cirrhosis (now known as Primary Biliary Cholangitis): An autoimmune condition where the immune system attacks the bile ducts, leading to cholestasis, liver damage, and cirrhosis.

Primary Sclerosing Cholangitis: An autoimmune disease causing inflammation and scarring of the bile ducts, which obstructs bile flow, leading to liver damage and cirrhosis.

Autoimmune Hepatitis: A condition where the immune system attacks liver cells, causing chronic inflammation and fibrosis that can progress to cirrhosis.

Idiopathic or Cryptogenic Cirrhosis: Refers to cirrhosis with no identifiable cause despite extensive investigation, where the liver damage and fibrosis occur without a clear underlying condition.

Clinical Manifestation and Complications ⁽⁴⁾:

The clinical presentation of liver cirrhosis can vary widely among patients. Some individuals may be asymptomatic, with the condition being discovered incidentally through imaging studies like ultrasound or during surgical procedures. Others might present with signs of liver enlargement (hepatomegaly) or spleen enlargement (splenomegaly), along with symptoms of portal hypertension such as variceal bleeding and ascites, or hepatic insufficiency. Common symptoms include generalized weakness, fatigue, abdominal discomfort, and nausea or vomiting. These manifestations reflect the underlying liver damage and impaired function characteristic of cirrhosis.

Homoeopathic approach for Liver cirrhosis ⁽⁶⁾⁽⁷⁾

Liver cirrhosis can be managed effectively through a homeopathic individuality approach, which emphasizes treating the patient as a whole rather than just addressing isolated symptoms. Homeopathic treatment aims to remove underlying causes and improve the patient's overall health, which can help mitigate pathological changes associated with cirrhosis. By evaluating the totality of symptoms, homeopathy provides a comprehensive portrait of the individual's disease condition, allowing for the selection of the most appropriate remedy, or "similimum." This approach not only addresses specific pathological damages but also supports overall liver function and well-being through targeted homeopathic remedies.

CASE REPORT

A 49 years old male patient residing in Nashikroad, Nashik came to outpatient department of Arihant Homoeopathic Clinic, on 11/6/24 (OPD no. I1 21/07) with diagnosis of Liver cirrhosis. He had following presenting complaints:

Abdominal pain aggravated lying on one side. Pain comes suddenly and pain continues for 7-8 days and pain subsides slowly. One pain starts and it shift to another pain, e.g. abdominal pain starts suddenly then knee pain commences or swelling of leg increases. Leg pain with swelling. All this complaints are since 3 years. Patient was diagnosed for liver cirrhosis with portal hypertension by an allopathic physician and was admitted to Allopathic hospital for treatment for many a times in last 3 years. Knee pain aggravated on rising from sit. Patient was afebrile.

HISTORY OF PRESENTING COMPLAINTS:

Patient had alcohol addiction. He use to consume alcohol daily. His complaints started suddenly with abdominal pain, nausea and vomiting, fever and weakness. He was admitted to hospital and treated for his complaints. Lab investigation and ultrasound sonography confirmed the diagnosis liver cirrhosis. Gradually patient started to develop complication like hemorrhoids, esophageal varices, splenomegaly, and portal hypertension. He also started to develop chronic kidney injury.

PAST HISTORY:- History of Hemorrhoids in 2023 which had been operated. Also history of raised cholesterol and hypertension.

FAMILY HISTORY: All are apparently healthy

PERSONAL HISTORY

Appetite:- Adequate, Two times/ day

Thirst: 2-3 litre/day, 1 glass at a time in 2 hours intervals

Desire: Sweets

Stool: Satisfactory

Urine: Day 6-7 times, Night 0-1 times no complaints **Sleep:**

6-7 hours hours/day, refreshing, sound sleep.

Thermal reaction: Hot patient

Perspiration:- Profuse on whole body when works in sun heat.

CONSTITUTION: Dark complexion, bilious appearance, Averagly Built Averagly Nourished person.

MENTAL STATE:

Patient had anxiety about health after he was asked to do no. of pathological reports by the then treating physician, general sympathy and is ambitious. Was upset with family members with dispute

since the members didn't responded well inspite of helping them in their bad times. Cannot tolerate wrong behavior.

GENERAL EXAMINATION

Blood pressure: 140/90 mm hg Icterus:
present on sclera

TOTALITY OF SYMPTOMS

1. Ailments from disappointment
2. Anxiety about health
3. Dispute in family
4. Ambitious
5. Abdominal pain < lying on one side
6. Leg swelling
7. Addiction alcohol
8. Chronic liver complaints

INVESTIGATIONS:

Blood reports:

- C reactive protein: 52.15 U/L
- Serum sodium: 133.1 mmol/l
- Haemoglobin: 10.2 g/dl
- Platelets count: 136000
- Hematocrit: 30.7 %

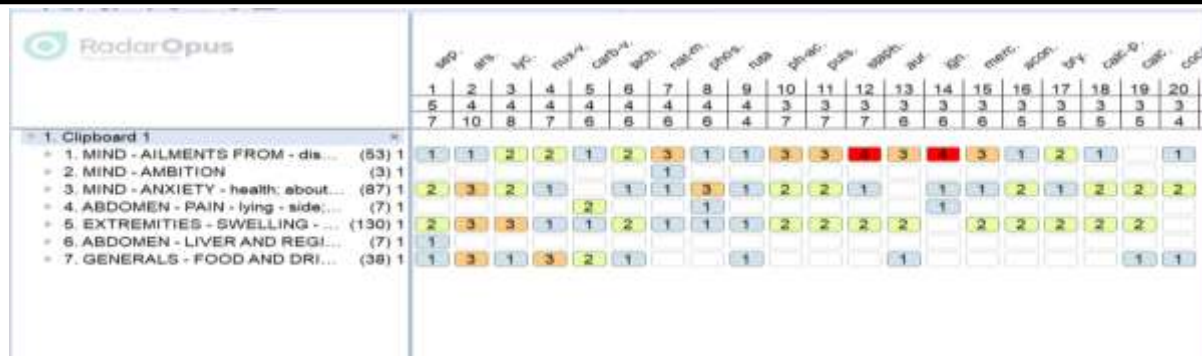Ultrasound sonography:

- Changes of liver cirrhosis
- Mild splenomegaly
- Dilated portal vein with reduced velocity (8.9cm/s)

DIAGNOSIS: Liver cirrhosis with portal hypertension

REPERTORIZATION

Repertorization was also done for this case by RADAROPUS repertory software. Following is the reportorial sheet.



SELECTION OF FINAL REMEDY

Natrum mur was chosen on the basis of symptoms : Ill effects of disappointment, Depressed particularly in chronic disease, sun aggravation.

Quercus glandium spiritus chosen on the basis of : Antidotes effect of alcohol. Dropsy and liver affections. Takes away craving for alcoholics. Useful in gout.

Chelidonium majus Q chosen on basis of : A prominent liver remedy. The jaundice of the skin.

SELECTION OF POTENCY

Considering the patient’s mind ailments from and mind symptoms Nat mur 200 potency was given. To reduce the craving and effect of chronic alcohol 30 potency of Quercus glandium spiritus was selected. Mother tincture was chose to overcome the pathological changes.

PRESCRIPTION

Natrum mur 200/ 2 doses/ Take at interval of 10 days

Quercus glandium spiritus 30/ 5 pills/ TDS/ For 20 days

Chelidonium majus Q/ 15 drops/ Half cup of water/ Before meal/ TDS/ for 20 days.

FOLLOW UP

Sr.no	Date	Complaints	Prescription
1	28/6/2024	No Abdominal pain Feeling relaxed and calm Icterus reduced on sclera Swelling of extremities is same as before Pain in knee joint no change	Quercus glandium spiritus 30/ 5 pills/ TDS/ For 30 days Chelidonium majus Q/


		Cystic swelling movable, non-congested, no pain present previously on right arm and now new one appeared on left arm too.	15 drops/ Half cup of water/ Before meal/ TDS/ for 30 days Calcarea flour 6X/ 2 tabs/ TDS/ 30 days
2.	27/07/24	No Abdominal pain Swelling of extremities is better than before Pain in knee joint no change < on rising from st, at night Cystic swelling movable, non-congested, no pain present previously on right arm and now new one appeared on left arm too. Scaly eruption on palms leaving behind blackish discoloration. Itching present on palms eruptions	Sulphuric acid 30/5 pills/ TDS/ For 30 days Calcarea flour 6X/ 2 tabs/ TDS/ 30 days Hydrastis mother tincture /15 drops/ Half cup of water/ Before meal/ TDS/ for 30 days
3.	12/9/24	No Abdominal pain Swelling of extremities is reduced Pain in knee joint no change < on rising from sit at night, starting movement. Cystic swelling movable no change. Scaly eruption on palms with discoloration is slight better.	Hydrastis mother tincture /15 drops/ Half cup of water/ Before meal/ TDS/ for 30 days Rhus tox 30 / 5 pills/ TDS/ For 30 days Calcarea flour 6X/ 2 tabs/ TDS/ 30 days

REPORTS:

BEFORE TREATMENT: MAY 2024



DURING TREATMENT: SEPTEMBER 2024



DISCUSSION: Liver cirrhosis, characterized by chronic liver injury and destruction of liver parenchyma, leads to severe complications and hampers normal liver function. Homeopathic medicine offers a promising approach to managing these degenerative changes. By focusing on organ-specific remedies in low potencies and utilizing mother tinctures, homeopathy aims to support liver function and mitigate structural damage. The principle underlying homeopathy is that derangement of the vital force leads to both mental and physical deterioration, which manifests as specific symptoms. This symptom totality helps in individualizing treatment to address the root causes of the disease.

In this case of liver cirrhosis, Natrum mur 200C was chosen as an individualized remedy based on a detailed case evaluation. Quercus glandium spiritus was prescribed to counteract the effects of alcohol, while Chelidonium mother tincture was used to support liver cell function. The treatment led to notable improvements, including reduced abdominal pain and enhanced mental well-being. This case underscores the potential of homeopathy to offer effective, side-effect-free management of liver cirrhosis, aligning with Dr. Kent's observations on the use of lower potencies and mother tinctures in chronic conditions and Dr. William Boericke's insights on organ-specific remedies. The patient continues to be under treatment, showing promising signs of recovery and improved quality of life.

CONCLUSION: Homeopathic treatment for major pathological condition like liver cirrhosis requires medicines on basis of totality of symptoms as well as organ specific for better and safe recovery of patient without any unwanted aggravation.

REFERENCE:

1. Ginès P, Krag A, Abraldes JG, Solà E, Fabrellas N, Kamath PS. Liver cirrhosis. *The Lancet*. 2021 Oct 9;398(10308):1359-76.
2. Zhou WC, Zhang QB, Qiao L. Pathogenesis of liver cirrhosis. *World journal of gastroenterology: WJG*. 2014 Jun 6;20(23):7312.
3. Schuppan D, Afdhal NH. Liver cirrhosis. *The Lancet*. 2008 Mar 8;371(9615):838-51.
4. Gupta DR. Efficacy of homoeopathic medicines in liver cirrhosis (Chronic liver disease). *Int J Hom Sci*. 2021;5(1):96-8.
5. Khan S, Patel S, Ahmad T, Yadav M. Liver cirrhosis with homoeopathic perspective.
6. REKHA DA. "A CLINICAL STUDY ON ALCOHOLIC LIVER DISEASE AND ITS HOMOEOPATHIC TREATMENT WITH CONSTITUTIONAL MEDICINE (Doctoral dissertation, Rajiv Gandhi University Of Health Sciences).
7. Ralston, S. H., Penman, I. D., Strachan, M. W. J., & Hobson, R. (2018). *Davidson's Principles and Practice of Medicine E-Book*. Elsevier Health Sciences.
8. Allen, H. C. (2022). *Allen's Key-notes Rearranged & Classified (10th Edition) With Leading Remedies of The Materia Medica & Bowel Nosodes*. B Jain Publishers Pvt. Limited.
9. Boericke, W., & Boericke, W. (2002). *Pocket Manual of Homoeopathic Materia Medica & Repertory*. B. Jain Publishers.
10. Kent, J. T. (1989). *Lectures on Homoeopathic Materia Medica*. B. Jain Publishers.
11. Jain, N. (2004). *Organon of Medicine*. B. Jain Publishers.

12. Kent, J. T. . Lectures on Homeopathic philosophy. B. Jain Publishers