

A case study of chronic otitis media treated with Homoeopathic simillimum**Kiran Tidke (PG scholar)****Abstract**

Otitis Media is the inflammation of middle ear cleft. Otitis Media is not only the most common bacterial infection in children, but also a leading cause of hearing loss in children. A 23 years old patient presented with the symptoms of yellowish, offensive, bloody discharge from right ear on and off with itching was treated successfully with Homoeopathic medicine Pulsatilla 200 which proved to be effective in chronic Otitis Media.

Keywords: Homoeopathic medicines, Otitis Media, Pulsatilla

Introduction:

Otitis Media represents an inflammatory condition of the middle ear. Factors believed to affect the occurrence of Otitis Media include age, gender, race, genetic background, socioeconomic status, type of milk or formula used in infant feeding, presence or absence of respiratory allergy, season of the year, pneumococcal vaccination status. Children with certain types of congenital craniofacial anomalies are particularly prone to Otitis Media.

The peak incidence and prevalence is from 6-20 months of age. The incidence of Otitis Media is greater in boys than in girls. Otitis Media is second in prevalence only to the common cold. The prevalence rate of acute Otitis Media in India is around 17-20% & Chronic Otitis Media is 7.8%.[1]

Classification of Otitis Media:-

1. Acute Suppurative Otitis Media – It clinically presents as tense and hyperemic tympanic membrane along with pain and tenderness and sometimes mastoiditis.
2. Chronic Suppurative Otitis Media – It manifests clinically as draining ear with perforated tympanic membrane and partially impaired hearing.

The most common organisms are streptococcus pyogenes, haemophilus influenza, pneumococcal and staphylococcus aureus. Chronic Otitis Media is the chronic inflammation of the middle ear and mastoid cavity, which presents with recurrent or persistent ear discharges (otorrhoea) for 2 to 6 weeks. The common causes of chronic Otitis Media are multiple episodes of acute Otitis Media, unhygienic conditions, low socioeconomic status. The common clinical features are ear discharge, hearing loss, earache, tinnitus, vertigo. Treatment includes use of antibiotics, nasal decongestant drops to improve drainage of middle ear through the Eustachian tube and analgesics to relieve pain and ear drops are also used.[2] Modern medicine provides a temporary relief and suppresses the problem.

Remedies for treatment of chronic Otitis Media includes Calcarea Carb, lycopodium, Pulsatilla, Silicea, Calcarea Ostrearum, Kali-Bich, Tellurium, Mercurius Solubilis, Hepar Sulph, Sulphur.[3]

Case Report:

A 23years male patient came on 15/09/2017 with complaints of:-

Presenting complaints:

Presenting complaints	Location	Sensation	Modalities	Concomitants
Pain and yellowish, offensive and occasional bloody discharge from right ear on and off. Since 4 years. [But increased since 3 months]	Right ear	Itching over the right ear	Aggravation by- cold food and drinks, ice cream. Amelioration by- cotton plug in ear.	Mild difficulty in hearing.

Past history:

Other mode of treatment taken for same ailments and then discharges stops since last 2 years, but same episode has occurred two times in a month.

Family history:

Mother – Hypertension. Father – Apparently healthy.

Personal history:

Desires: sweets. Aversion: ghee.

Appetite: adequate. Thirst: 4 to 5 glass/ day.

Urine: 4 to 5 times/ day. Stool: once/ day.

Allergies: not specific. Dreams: not specific.

Sleep: sound. Constitution: well built. Wheatish Complexion.

Thermal state: Hot

	Summer	Winter	Rainy
Covering	×	✓	×
Fan	✓	×	×
Bathing	Luke warm	Luke warm	Luke warm
Tolerance	Cold	Cold	Cold

Physical examination:

Pulse: 76/min. B.P.: 120/70mm of Hg

No pallor.

Systemic examination:

Respiratory system: Air entry bilaterally equal. Central nervous system: conscious and well oriented.

Cardio vascular system: S1 S2 normal. P/A: soft and non- tender.

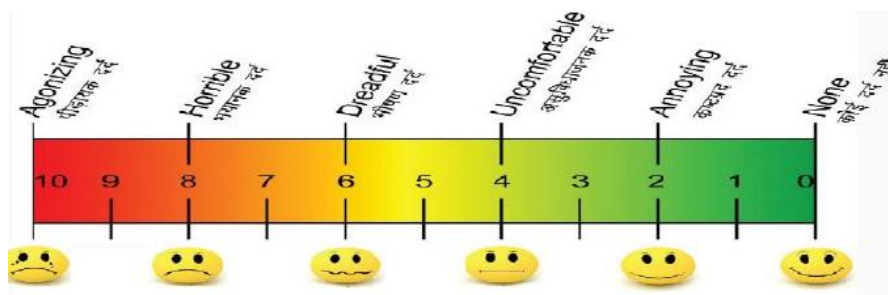
Local examination:

Right ear – yellowish, watery, offensive discharge. Left ear – wax.

Hearing test: 1. Rinne test – positive (air conduction is greater than bone conduction).

2. Weber test – sound is heard when tuning fork is placed in midline.

Visual Analogue Scale: 8



Mental state:

- The patient was having financial tension. He wants to do education in technical line but due to money problem he did graduation.
- Anxiety about what will happen in future.
- Still he is unable to decide whether to stay in same job or should change.
- Care, feeling and love for others.

Analysis:

Presenting complaints	Location	Sensation	Modalities	Concomitants	Classification of symptoms
Pain and discharge from right ear on and off	Right ear	Itching over the right ear	<- cold food and drinks, ice cream. >- cotton plug in ear.	Mild difficulty in hearing in right ear	complete particular symptom
Discharge yellowish, offensive, bloody	Right ear				Incomplete particular symptom
Desire sweets					Physical general symptom
Aversion ghee					Physical general symptom
Thermals Hot					Physical general symptom
Financial tension					Mental general symptom
Irresolution					Mental general symptom
Affectionate					Mental general symptom

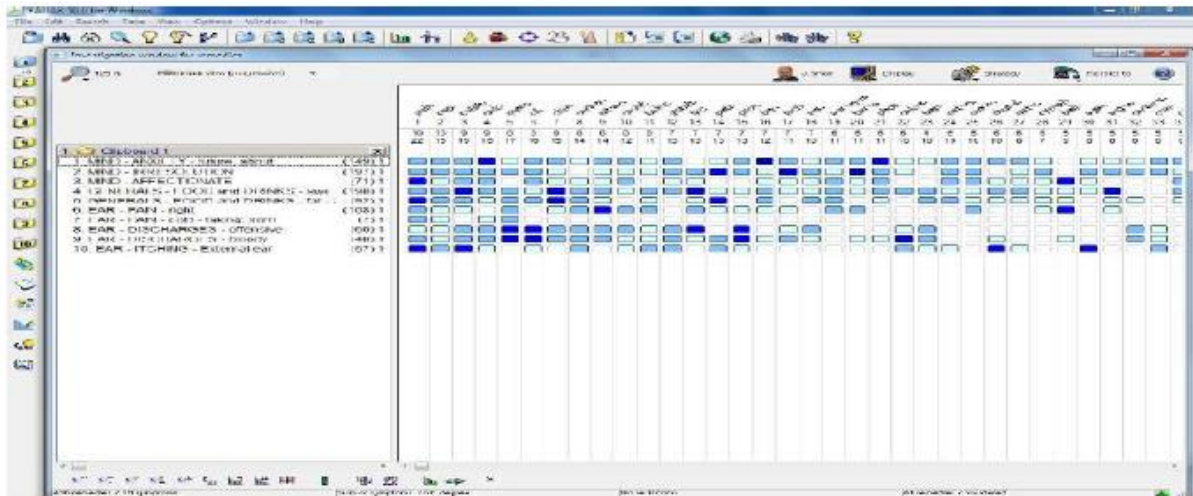
Evaluation:

- Financial tension. -Irresolution.
- Affectionate. -Desire sweets.
- Aversion ghee. -Thermals Hot.
- Pain and discharge from right ear on and off. Aggravation - cold food and drinks.
- Discharge yellowish, offensive, bloody. - Itching.

Final Diagnosis:

Chronic otitis media. Case was repertoried on the following symptoms by using RADAR 10. (Schroyens F. synthesis 9.0).

Repertorization:



Prescription:

Pulsatilla 200 x 3 doses x 8 hourly Sac Lac 30 x TDS x 15 days.

Follow up: 1/10/2017

- Pain and discharges from right ear decreased than before.
- Bloody discharge from right ear decreased in last 15 days.
- But complaints aggravates after taking cold.
- Now no itching over the right ear.
- Difficulty in hearing decreased.

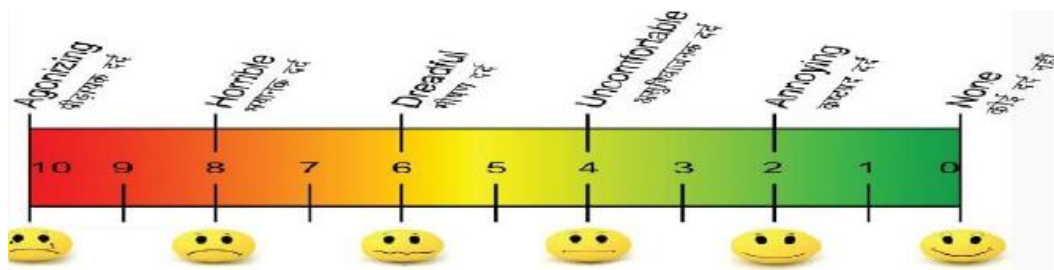
Visual Analogue Scale: 4

Prescription: Sac lac single dose Sac Lac 30 x TDS x 15 days

Follow up: 16/10/2017

- Pain and discharge from right ear decreased.
- No bloody discharge from right ear. - No itching over the right ear.
- No difficulty in hearing. - Complaints are better now.
- No new complaints.

Visual Analogue Scale: 2



Conclusion:

1. As per the visual analogue scale study, the intensity of pain has reduced.

2. The frequency of disease before treatment 2 times in a month has reduced to 0 per month for two consecutive months.
3. Thus, from above study researcher has concluded that after administration of homoeopathic simillimum the condition under study, that is chronic Otitis Media improved substantially.
4. Researcher is still observing the case for any recurrence.

Discussion:

1. Homoeopathic medicines like Pulsatilla, Merc Sol, Calcarea Carb, Silicea, Sulphur, Graphites, and Hepar Sulph are usually found on Repertorization.
2. After reportorial study the knowledge of Materia medica, therapeutics, guides us to reach up to Homoeopathic simillimum medicines.
3. In the Otitis Media like conditions conventional conservative medicines have limited role and surgical treatment doesn't assure the permanent cure.

References:

- 1) Mohan Bansal. Essentials of Ear, Nose and Throat. 1st edition. New Delhi: The Health sciences publisher; 2016. p. 101.
- 2) Harsh Mohan. Textbook of Pathology. 6th edition. New Delhi: Jaypee Brothers Medical publishers (P) ltd; 2010. p. 514.
- 3) Boericke. W. Pocket Manual of Homoeopathic Materia Medica and Repertory. Rep. ed. New Delhi: B Jain Publishers: 1998.
- 4) Radar 10.5 (Schroyens F. synthesis 9.0).