
Eczema Cured by Calcarea Carb- A Case Report

¹PROF DR. Yogeshwari Gupta*

MD (Hom), Former Dean Homeopathy Rajasthan Ayurved University, Jodhpur; Principal & HoD Materia Medica, Swasthya Kalyan Homoeopathic Medical College and Research Centre, Jaipur, Rajasthan, India.

²Dr. Nitiksha Sharma

MD (PGR), Materia Medica, Swasthya Kalyan Homoeopathic Medical College and Research Centre, Jaipur, Rajasthan, India.

Corresponding author:

Address: Swasthya Kalyan Homoeopathic Medical College and Research Centre, Jaipur, Rajasthan, India.

Contact No: 9414229555

Mail Id: doctoryogeshwari@gmail.com

Abstract: Eczema is a chronic skin condition. The global prevalence of eczema is 2.3% for both sexes. The word "eczema" refers to the eczematous character of this illness, which manifests as blister development, serous leaking, rusting, erythema, and scaling. It may affect individuals in their adult years. Calcarea carbonicum is the great Hahnemanian anti-psoric remedy. Calcarea is one of the homoeopathic remedy which has to be chosen for the various dermatological cases based on individualization. Calcarea carbonicum may be considered when constitutional symptoms accompany eczema. Homoeopathic remedies were based on numerous experiments and validation. "Homeopathy is a form of alternative medicine that follows certain principles to treat a person."

This case study helps to enhance our knowledge of treating the individual who is suffering from dermatological difficulties in which eczematous eruptions is the one. This study could be beneficial during practising and provided us with a way to approach Calcarea Carbonium. Homoeopathy relies on the best possible treatment and the expertise of the treating physician.

Keynotes: Calcarea Carbonicum, Eczema, Individualized Homoeopathic medicine, Case-report.

Introduction: Calcarea is essential for various bodily functions, such as maintaining healthy blood coagulation, heart function, nervous system upkeep, and muscular contraction. ⁽¹⁾ In case of a deficiency, individuals may experience symptoms such as depression, poor intellectual performance, irritability, and anxiety. ⁽²⁾ They may also have difficulty articulating with unintelligible speech. The Calcarea group of medicines is differentiated according to the

individual's constitution, reflecting their uniqueness. ⁽³⁾ Anxiety and delusions are typically associated with Calcarea. ⁽³⁾ Eczema is a type of skin inflammation that is characterized by redness, itching, scaling, vesicles, crusting, weeping, and lichenification. Although eczema and dermatitis are interchangeable terms, they are commonly used to describe atopic dermatitis, which is the most prevalent type of dermatitis. The primary causes of recurrent inflammatory skin conditions, such as eczema, include a compromised skin barrier, immunological dysfunction, family history, and environmental contamination. Itching is the primary symptom of the disease. ⁽⁴⁾

The appearance of atopic dermatitis, which is commonly known as eczema, can vary depending on the age of the person. ⁽⁵⁾ According to homeopathy, extensor eruptions and lichenification are the main characteristics of eczema. The primary cause of eczema is the underlying genetic predisposition to produce immunoglobulin E (IgE) antibodies. ⁽⁶⁾ Eczema can also have an impact on our emotional well-being, which can be addressed through homeopathic treatment. ⁽⁷⁾

Case- Report:

Presenting Complaint:

A 50 years old age female came to our OPD at Swasthya Kalyan Homoeopathic Medical College and Research Centre, Jaipur, Rajasthan with the complaint of eczematous eruption on the Right ankle since 8-9 years. The affected skin was dry, cracked, thickened. There was intense itching, bleeding after scratching.

Modalities: < Itching after washing and on the exposure of open air.

History of presenting illness:

Patient had mild itching in winters, then it increases gradually. She starts taking allopathic medicines which rapidly aggravated the itching but got no relief in eruptions. Since 5 years all complaint of the patient were aggravated with the persistent itching, dryness and cracks over the right ankle.

Family History:

Maternal Side: Both Died (Natural death).

Paternal Side: Healthy and alive.

Personal History:

Addiction: N/S

Bathing Habit: Regular

Sexual History: Healthy and satisfactory.

H/O of vaccination- all done.

H/O any other medication and allergies: N/S

Gynecological History:

Menarche- at 11 years of age.

LMP- 16/07/23

Cycle- regular, 4-5/ 28-30 days.

Flow- profuse bleeding on 2nd and 3rd day, bright red in color.

Obstetric History:

G2 P2 A0 L2

She has one male child and one female child through normal vaginal delivery.

Physical generals:

Appetite: Average

Thirst: Average

Desire: Sweets

Aversion: Not specific

Stools: Constipation (Due to fast foods)

Urine: Normal and clear.

Perspiration: profuse on scalp, with yellow staining.

Thermal: Hot

Mental Generals:

Patient often experienced anxiety and exhibited a high level of forgetfulness. She was confused, poorly articulated and slow to perceive with inability to reply. She was an introverted person. She wanted some support before coming to any decisions. She said that she had too much anxiety when she closed her eyes. Dullness (During observation). Weakness of memory. Delirium in the dark (Feels everything is in dark).

Clinical Observation:

Built: Average

B.P: 126/84 mm Hg

Pulse: 78/ minute

Respiratory Rate: 17/ minute

Temperature: 98.6 F

Weight: 68 kg

Height: 158 cm

Diagnosis:

Atopic Dermatitis (Eczema), (ICD- 10 Classification: L20.9)

Table 1: Analysis of Symptoms.

Mental General	Physical General	Particulars
Patient was very forgetful and having anxiety most of the times during work	Desire- Sweets	Eruptions on right ankle
She wants support for taking any decisions.	Perspiration- Profuse on scalp with yellow staining.	Dry, Cracked eruptions with severe itching.
She had too much anxiety when she closed her eyes	Stools- Constipation.	Bleeding after scratching.
Dullness.		
Weakness of memory.		
Delirium in the dark.		
Introverted person		

Table 2: Miasmatic analysis showing predominant Psora miasm ⁽⁸⁾

S.No.	Symptoms	Psora	Syphillis	Sycosis
1	Forgetful	✓		
2	Anxiety	✓		
3	Dullness		✓	✓
4	Delirium dark in	✓		
5	Memory wekness	✓		
6	Introverted person	✓		
7	Support desire	✓		
8	Desire for sweets	✓		

9	Perspiration profuse on scalp		✓	✓
10	Constipation	✓		
11	Eczematous eruption	✓		
12	Cracks on ankle		✓	
13	Itching	✓		
14	Bleeding after scratching		✓	

Totality of Symptoms:

Patient was very forgetful and having anxiety most of the times during work

She wants support for taking any decisions.

She had too much anxiety when she closed her eyes

Dullness (During observation)

Delirium dark in

Introverted person

Desire for sweets

Perspiration profuse on scalp

Constipation

Eczematous eruption

Cracks on ankle

Itching Bleeding after scratching

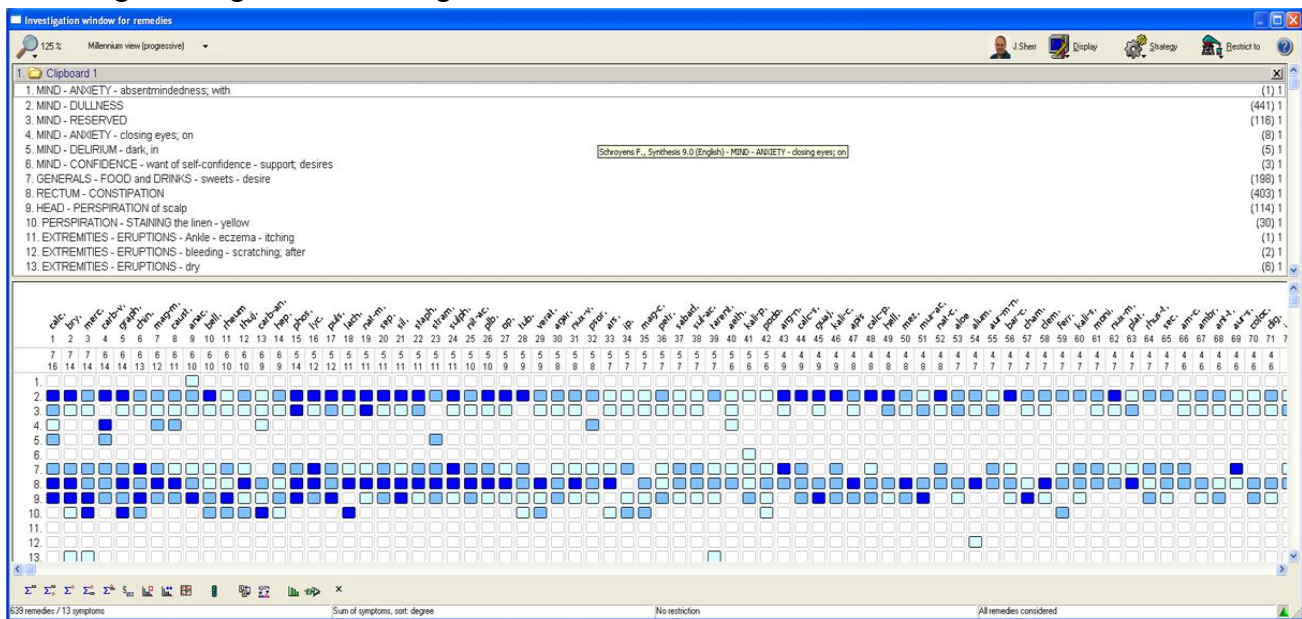


Fig 1: Repertorial Sheet

Rubrics:

Mind-Anxiety-absentmindedness, with

Mind- Dullness

Mind- reserved

Mind- anxiety-closing eyes, on

Mind- delirium-dark, in

Mind- confidence-want of self -confidence- support, desire

Generals- food & Drinks- sweets- desire

Rectum- constipation

Head- perspiration of scalp

Perspiration- staining the linen- yellow

Extremities- eruptions-itching - itching

Extremities- eruptions- bleeding- scratching, after

Extremities- eruptions- dry

Repertorial result:

Calcarea- 17/8

Bryonia- 14/7

Mercurious- 14/7

Carbo- veg- 14/6

Graphites- 14/6

China- 13/6

First prescription with Justification: (12/08/23)

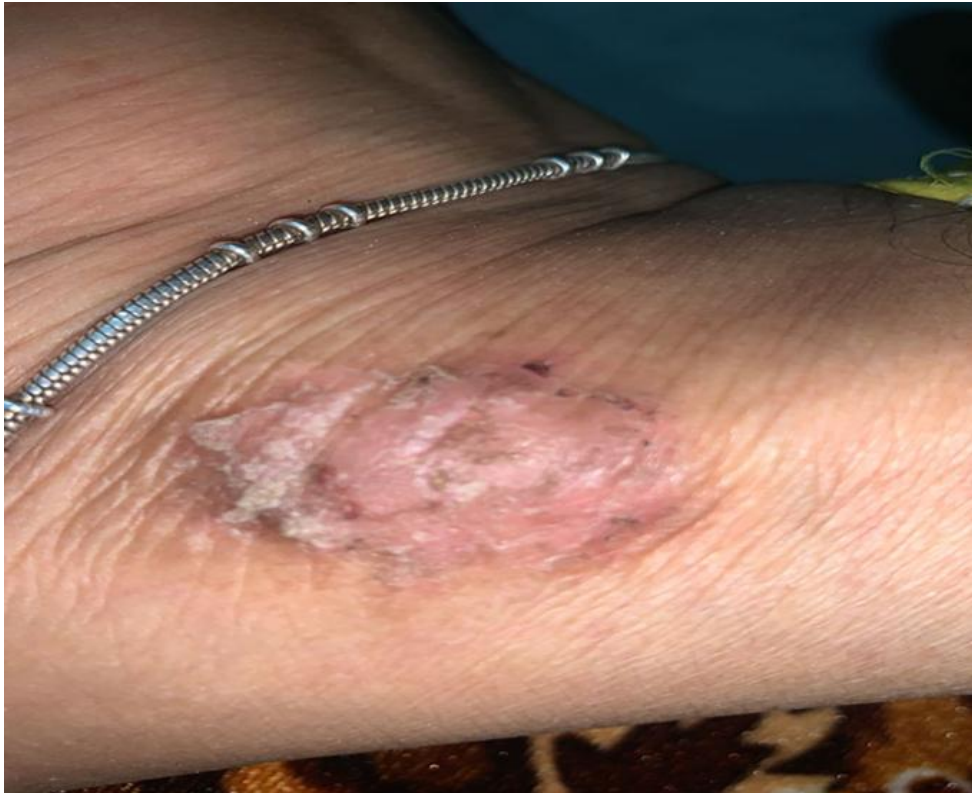R_x

Calcarea Carb 30/ 1 Dose/ H.S.

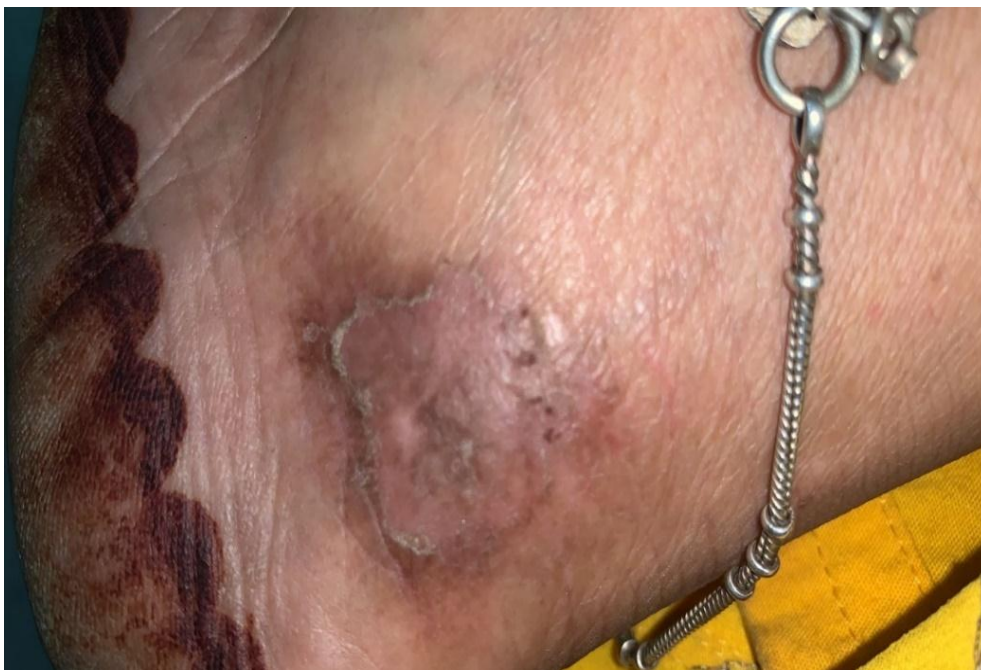Rubrum 200/ T.D.S. for 15 days.

Calcarea carb was selected after proper analysis of the symptoms on the basis of mental, physical, particulars symptoms totality was constructed. Repertorial analysis were done with the help of synthesis repertory English (0.9) RADAR 10 Software. Calcarea Carb was selected after proper symptom similarity and it covers maximum rubrics. 30C was selected on the basis of susceptibility of the patient.

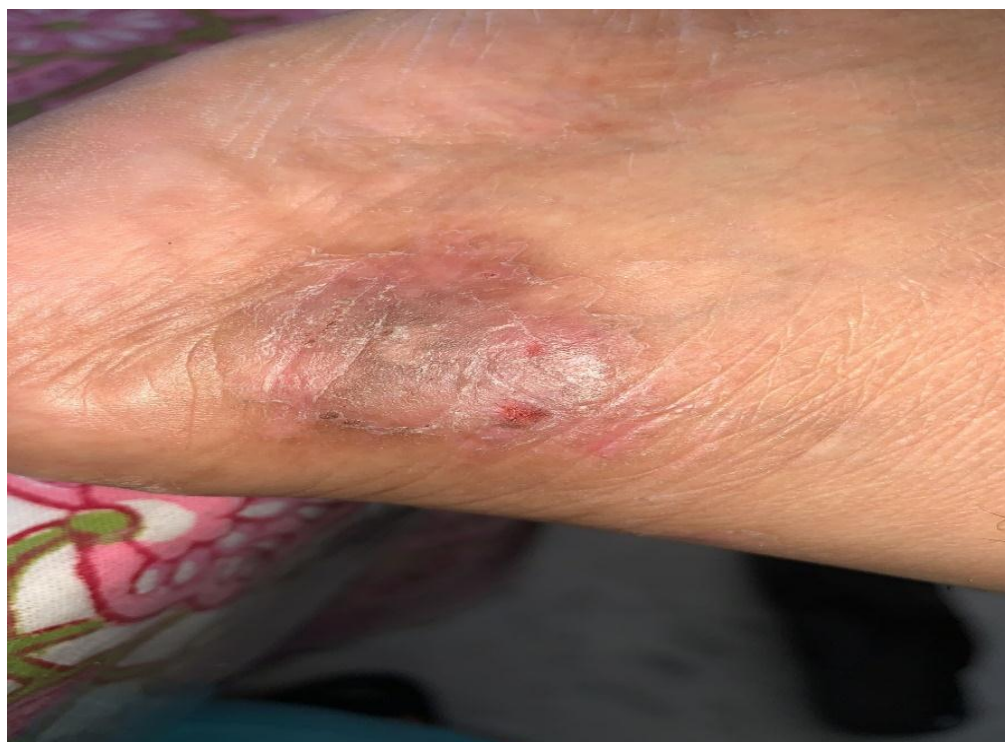Pretreatment picture of eczematous eruption on right ankle (28/08/23)



During treatment picture of eczematous eruption on right ankle (1/10/23)



Post treatment picture of eczematous eruption on right ankle (25/12/23)



Follow- ups with prescription:

Date	Changes in Symptoms	Prescription	Justification of potency and doses
28/08/23	Eruptions aggravate Itching and scratching are too intense. Bleeding after scratching. Cracks are still present.	R _x Phytum 30 / TDS/ 15 days	Calcarea acrb was stopped as the symptoms are aggravated then patient is on placebo.
14/09/23	Slight relief in eruptions Itching was slightly relieved (30%) Bleeding after scratching was also slightly relieved. Cracks are still persisted. No relief	R _x Rubrum 30/ 1Dose Phytum 200/ T.D.S. 15 days	Patient is on placebo due to slightest relieve in symptoms.
1/10/23	>>> relieve in eczematous eruptions. >>> Relieve in itching around (40%) Coryza due to changing weather. < on warm room	R _x Allium Cepa 30/B.D. 5 Days	Remedy was chosen due to acute condition

	>In open air Now slightly relive in cracks.		
12/10/23	60% relieve in eczematous eruption. Relieve in itching. On 9 October bleeding was relieved after scratching. Relive in cracks too. Relieve in coryza.	R _x Phytum 30/ 1 Dose/ H.S. Rubrum 200/ T.D.S. 1 Month	Placebo was given due to amelioration in symptoms.
15/11/23	70% more relieve in eczematous eruption. Relieve in itching There is no bleeding after scratching. Relieve in cracks. There are no concomitants.	R _x Phytum 200/ T.D.S. 1 month	Placebo given due to relieve in symptoms.
25/12/23	Relieve in cracks. Relieve in eczematous eruption with itching. There is no bleeding. Patient said she feels better nowadays. Overall improvement in eruptions.	R _x Rubrum 30/ 1Dose Phytum 200/ T.D.S.	Due to relieve in symptoms.

Discussion and conclusion ⁽⁹⁾: Eczema is a skin condition characterized by inflammation, dryness, scaling, and itching. It can significantly reduce the quality of life. Chronic diseases, eczema which were gradually increases it affects the person day to day lifestyle. Individualized homoeopathic medications should be used to treat skin illnesses since, in accordance with homoeopathic principles, their suppression leads to a deeper sickness. Calcarea carb was prescribed on the basis of individuality of the patient which are basically constructed on homoeopathic principles. Calcarea carbonicum adopts a comprehensive approach to curing, considering the overall wellbeing of the patient.

A predominant miasm involved in the case of eczema is psora. Of the hundreds of cures available, only one is most similar to each individual, applied gently and mildly, and beneficial for people of all ages. The physician's attention, patience, or awareness are required for homoeopathy.

This case study will help to ascertain the role of calcarea carbonicum 30 (single dose) to advance our knowledge in the field of individualization. Calcarea carbonicum remedy was involved in curing the eczematous eruptions when individualization has been done. This could be a ray of hope for signifying its importance.

References:

- 1) Me A. A study on calcarea group of medicines with special emphasis on calcarea phosphorica [Internet]. Homeopathy Resource by Homeobook.com. Homeobook; 2020 [cited 2024 Jan 13]. Available from: <https://www.homeobook.com/a-study-on-calcarea-group-of-medicines-with-special-emphasis-on-calcarea-phosphorica>
- 2) Me A. Calcarea group of homeopathy Medicines [Internet]. Homeopathy Resource by Homeobook.com. Homeobook; 2012 [cited 2024 Jan 13]. Available from: <https://www.homeobook.com/calcarea-group-of-homeopathy-medicines>
- 3) Maiti BP. Eczema treated with individualized homoeopathic medicine: A case report. *International Journal of Homoeopathic Sciences*. 2023;7(2):40-44.
- 4) Das M. Atopic dermatitis: case series of individualized homoeopathic treatment. *Int J Health Sci Res*. 2021; 11(11): 115-123
- 5) Garg H., Gontiya R., Effect of Homoeopathic Medicine on Quality of Life in Children with Atopic Dermatitis: A Prospective Observational Study. *TUJ. Homo & Medi. Sci*. 2022;5(1):11-25.
- 6) Meena BS, Kumar A, Bagdi N. A case of eczema treated with homoeopathic medicine. *Journal of Integrated Standardized Homoeopathy* [Internet]. 2020 [cited 2024 Jan 13];3(20):20–3. Available from: <https://jish-mltrust.com/a-case-of-eczema-treated-with-homoeopathic-medicine>
- 7) Biagini Myers JM, Khurana Hershey GK. Eczema in early life: genetics, the skin barrier, and lessons learned from birth cohort studies. *J Pediatr*. 2010 Nov;157(5):704-14. doi: 10.1016/j.jpeds.2010.07.009. Epub 2010 Aug 24. PMID: 20739029; PMCID: PMC2957505.
- 8) Patel RP. Chronic Miasms in Homoeopathy and their cure with classification of their rubrics/ symptoms in Dr. Kent's Repertory. Hahnemann homoeopathic pharmacy, Kerala, 1996.
- 9) Roll S, Reinhold T, Pach D, Brinkhaus B, Icke K, Staab D, Jäckel T, Wegscheider K, Willich SN, Witt CM. Comparative effectiveness of homoeopathic vs. conventional therapy in usual care of atopic eczema in children: long-term medical and economic outcomes. *PLoS One*. 2013;8(1): e54973. doi: 10.1371/journal.pone.0054973. Epub 2013 Jan 31. PMID: 23383019; PMCID: PMC3561412.