

---

**CASE REPORT****Homoeopathic management in a case of massive splenomegaly with multiple enlarged gastric lymph nodes – (suspected of myeloproliferative disorder)****Dr. Sarang rahalkar****Abstract**

Myeloproliferative disorders (MPD) are types of blood cancer caused by changes in the stem cells in which number of red blood cells, white blood cells and platelets increases abnormally in the bone marrow. Current treatments are Allogeneic Stem Cell Transplantation, targeted drugs, chemotherapy and immunotherapy.

This is a case of a lady, 54years old presented at Astha Homoeopathic Clinic with complaints of numbness, heaviness, tenderness and dull aching pain at left hypochondriac region. Investigations showed massive enlargement of spleen up to 20.5cm and multiple enlargements of lymph nodes suspected as Myeloproliferative disorder (Chronic myeloid leukaemia). There was also hepatomegaly and dilated portal vein(1.5cm).

The patient was interviewed in detail according to Hahnemannian Homoeo Forum [HHF] method where emphasis was given on the personality, the concern, adaptation and psychodynamic understanding of the disease to select the similimum.

The homoeopathic treatment resulted in gradual resolution of the enlarged spleen from 20.5cm to 11.3cm. Hepatomegaly was resolved. Enlarged pre and para aortocaval lymph nodes also regressed after 3-4 months.

The case demonstrated effectiveness of standardised homoeopathic treatment selected on the basis of individuality in order to restore health with good quality of life in rapid and gentle way even in the grave pathology.

**KEY WORDS:**

HOMOEOPATHY, INDIVIDUALISATION, HHF, PSYCHODYNAMIC, MPD.

**Introduction**

Myeloproliferative disorder (MPD) are types of blood cancer caused by changes in the stem cells inside bone marrow, the tissue that make blood cell. It is a type of a disease in which number of red blood cells, white blood cells and platelets increases abnormally in the bone marrow. The most common symptoms which we see is weakness, pain in abdomen, fatigue, loss of appetite, shortness of breath during exertion, pale skin, prolong bleeding from minor cuts and purpura [1]. The only curative treatment known is Allogeneic Stem Cell Transplantation. Other treatment includes targeted drugs, chemotherapy and immunotherapy [2].

The lady of 54 years old came to Astha Homeopathic clinic (Nashik) with her daughter on **08/09/2020**. She had c/o heaviness and numbness at left hypochondriac region with dull aching pain, heaviness and tenderness causing difficulty in walking.

After receiving the presenting complains she was asked about her concern and mental stress to which she replied, that she doubted it to be due to intake of cow's milk and exercise due to which she lost her weight. To increase weight she started taking ghee, olive oil, milk 1 – 1 1/2 liters daily. She was suspected of cholelithiasis during that period.

As the things progressed, she started feeling hardness, heaviness and tenderness around left hypochondriac region. She thought that because she had started eating very much it might be some muscle enlargement. But then they decided to do USG of abdomen. Further she said that she feels afraid to take milk or any of these fatty foods now. Her MRI and USG were showing massive splenomegaly with spleen measuring about 20 cm, displacing the transverse and descending colon inferiorly. There were also multiple enlargements of lymph nodes and she was suspected to have myeloproliferative disorder (chronic myeloid leukemia). Also had hepatomegaly, with dilated main portal vein.

She was been told by the oncologist to go for chemotherapy to which she denied but instead she opted to take homoeopathic treatment.

### **Life space situation-**

The major conflict in her life was her relationship with her husband. She suspected that her husband has an affair with another lady which she got to know by looking at his social media accounts, she even narrated that her husband was of flirty nature.

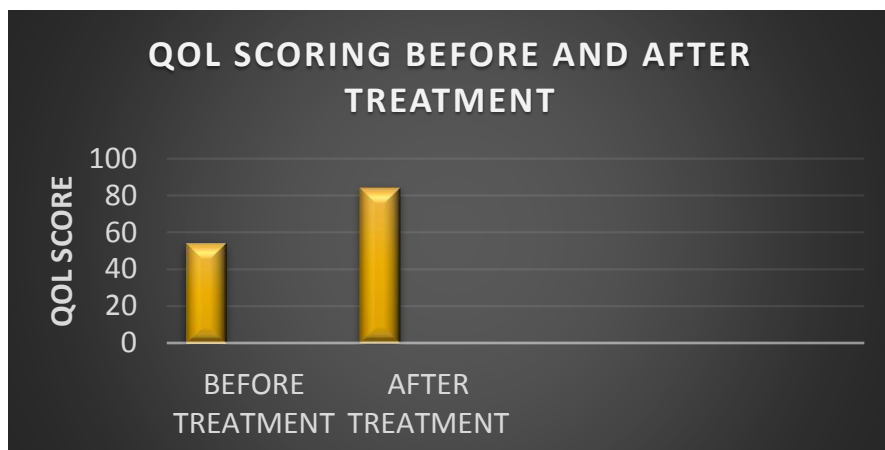
When confronted with husband about it, he responded in a weird manner, to which patient was very much hurted. She was very angry with the situation but never overtly reacted or revolted.

Instead, they both stopped talking with each other for more than 6 months. On asking about what she felt during that period she replied that she felt very much angry inside making a gesture of slapping. To maintain harmony in her house, she never broke the relationship and expected that husband should accept his mistake so that everything would be fine between them. She said that she had already forgiven him.

She maintained her dignity but not talking to husband but doing everything needful in the house. Throughout her case she was very mild, gentle and soft spoken. It seemed that she had swallowed her anger and a mask of kindness and good nature is shown in front. We can understand her internal turmoil and anger while she was talking, but she has continued her relationship so that the family would not get disturbed. At the same time, she even respects and loves her husband very much. Throughout her case it was felt that she has maintained her dignity and respect towards husband and others while trying to keep everything in balance.

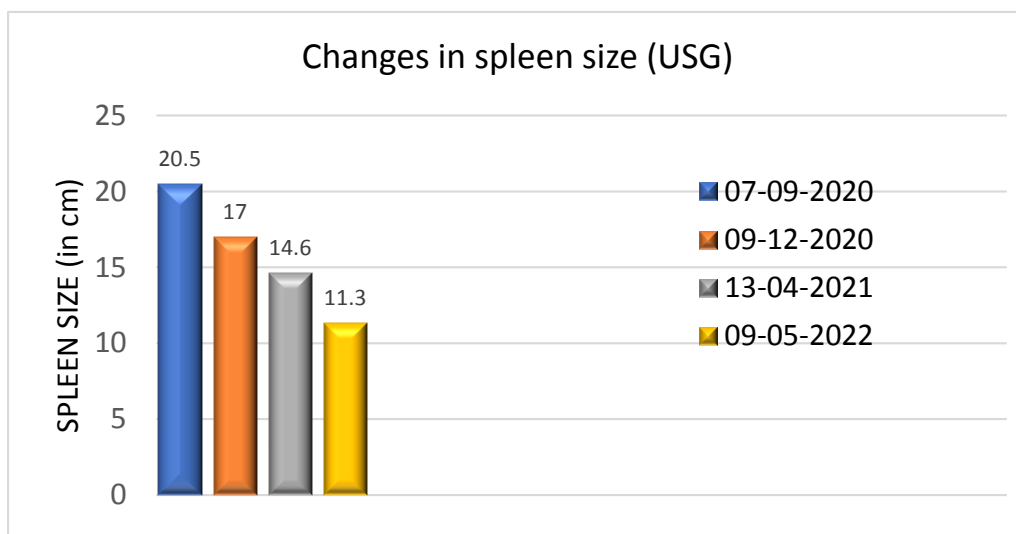
For qualitative purpose, the patient was assessed using quality of life scale [QOL], which has 16 questions related to five different categories, for obtaining a total score before treatment<sup>[3]</sup>.

**RESULT:**



**Fig. 1-Quality of life (QOL) scoring before and after Homoeopathic treatment**

The above figure no- 1 represents the score of quality-of-life scale by Flanagan, in which the score before treatment was 54 and after treatment score was 84 signifying the improved quality of life of the patient in physical and material well-being, relationship with other people, activities and personal development categories by homoeopathic treatment.



**Fig – 2. Changes in spleen size during the Homoeopathic treatment**

The figure no – 2 represents after the homoeopathic similimum there was complete resolution of the enlarge spleen from 20.5cm to 17cm in 3 months to 14.6 cm in 4 months and followed by resolution to 11.3cm.

Hepatomegaly was resolved. Enlarged pre and para aortocaval lymph nodes also regressed after 3-4 months of treatment. Uterus which was bulky came to normal. After similimum patient reported with internal well-being and there was considerable improvement in the patient clinically and mentally, with good quality of life.

---

## Discussion

Due to suppressed anger and stress there is continuous affection on the immunological system of body, which is directly correlated to psycho- neuro- immunological aspect where we find spleen is affected first. When there is continuous emotional stress due to anger, anxiety, nervousness, there is a prompt release of stem cells from the bone marrow to the spleen, due to which there is flood of white blood cells, or monocytes, platelets and expand over time, which leads to splenomegaly<sup>[4]</sup>.

Homoeopathic practice is based on individualisation i.e., we treat the person in the disease and not only disease<sup>[4]</sup>. In HHF we even give emphasis on the past, present and persistent ailments. To individualise and characterise the patient we give more importance to mental symptoms. In the present case the important facet of this lady is the way she has handled the situation in crises.

The way she narrated her situation about her relationship with her husband seems to be so MILD that it was very peculiar, how can a lady be so REFINED and GENTLE while talking about all such things though there was an internal turmoil.

She was telling the entire situation in a GENTLE, SOFT AND IN A MILD WAY

Though we find a degree of sensitivity and hurt in her but at the same time we do not see any kind of a revolt made by her.

She was HURT by all this situation but overtly she was not showing it to anybody.

In the entire case important thing to be marked was her DIGNITY but at the same time she was maintaining the proper harmony in the house.

It seems that she has put up A FALSE SHOW in front.

She has maintained her DELICACY and KINDNESS with DIGNITY.

The important thing is that she DO NOT WANT TO BREAK THE RELATIONSHIP at all.

She even tells that she has FORGIVEN HER HUSBAND.

This shows her BENOVOLENT and SYMPATHETIC nature.

We can see her keeping a lot of PATIENCE and CALMNESS but inside seems to be having lot of SADNESS, ANGER and ESTRANGEMENT TOWARDS HER HUSBAND.

### REPORTORIAL TOTALITY USING SYNTHESIS REPERTORY<sup>[6]</sup>

MIND – MILDNESS

MIND - YIELDING disposition

MIND – SYMPATHETIC

MIND - HARMONY - desire for

MIND – BENEVOLENCE

MIND – DIGNIFIED

MIND – DISCONTENTED

MIND - ESTRANGED - husband; from her

MIND - FORSAKEN feeling

MIND - INJUSTICE, cannot support

MIND – RESERVED

MIND - SELF-CONTROL – increased

MIND - AILMENTS FROM - anger - silent grief; with

ABDOMEN - PAIN - Spleen - walking - agg.

ABDOMEN - PAIN - Spleen - pressing pain

ABDOMEN - INFLAMMATION - Spleen

ABDOMEN - PAIN - Spleen

ABDOMEN - DISTENSION – Spleen

Considering the above set of rubrics, correlating it with the personality of the patient and Materia medica literature of various stalwarts [7 - 14], the remedy selected as similimum was Natrum Carbonicum.

Looking at the grave pathology, structural changes and generalities selected potency was 30 C with daily dose at night of 4 globules for 1 month.

### **Follow-up:**

**29/09/2020 –**

Stony feeling at right hypogastric region not present, tenderness is absent, feeling of internal wellbeing reported by patient. Appetite improved, irritability reduced.

R<sub>x</sub>

Natrum Carb 30 C / weekly one dose / 1 month,

Sac Lac / 4 pills/ BD/ 1 month.

**30/10/2020-**

Generalised weakness reduced, negative thoughts and irritability reduced, Abdominal tenderness is absent, feeling fresh now, mentally completely better.

R<sub>x</sub>

Natrum Carbonium 200 / 4 pills/ 1 dose weekly/ 1 month

Sac Lac / 4 pills/ BD/ 1 month.

**21/11/2020 –**

Generalised weakness completely reduced, spleen palpable 2 fingers, no tenderness present.

R<sub>x</sub>

Sac Lac / 4 pills/ BD/ 1 month.

**09/12/2020 –**

Patient is feeling mentally and generally better.

USG reports – spleen size 17 cm.

Feedback by daughter - since she is mentally better, dad is also fine now.

R<sub>x</sub>

Sac Lac / 4 pills/ BD/ 1 month.

**13/04/2021 –**

USG reports done – spleen size 14.6 cm with general well being.

R<sub>x</sub>

Sac Lac / 4 pills/ BD/ 1 month.

**24/06/2021 –**

Patient is completely better with no complaints of pain and gastric disturbance.

Mentally, she feels relaxed, positive and happy.

R<sub>x</sub>

Sac Lac / 4 pills/ BD/ 1 month.

**09/05/2022-**

USG reports – Normal spleen size 11.3 cm, liver size normal and complete resolution of pre and para aortocaval lymph nodes is noted. patient is mentally and physically better.

R<sub>x</sub>

Sac Lac / 4 pills/ BD/ 1 month.

Considering the example of the above case and many other grave pathological cases treated by Homoeopathy there is further scope for research to creating a standardised Homoeopathic approach.

## CONCLUSION:

Homoeopathy acts unconditionally in a most rapid and a gentle way even in grave pathologies. It has no side effects and is even cost effective and thus we can avoid surgical intervention in many cases.

Thus, when the Homoeopathic similimum is selected on the Mind Body and Soul axis as we are trained in HHF the patient is treated holistically. The patient is not only cured of his physical ailments but also harmony is maintained mentally.

**Supplementary Materials:** The following supporting information can be downloaded at:

Burckhardt CS, Anderson KL, Archenholtz B, Hägg O. The Flanagan Quality Of Life Scale: evidence of construct validity. Health Qual Life Outcomes. 2003 Oct 23;1:59. doi: 10.1186/1477-7525-1-59. PMID: 14613563; PMCID: PMC269996.

**Informed Consent Statement:** The authors certify that; they have obtained the appropriate patient consent form.

**Acknowledgments-** I hereby acknowledge Dr. Neelam Rahalkar, Dr. Sanket Lodha and Dr. Reena Bhanushali for their contribution in technical support.

**Conflict of interest:** The author declares no conflict of interest

## References

1. <https://hillman.upmc.com/cancer-care/blood/types/mpd>
2. Ralston S, Penman I, Strachan M, Hobson R. Davidson's Principles and Practice of Medicine - 23rd Edition.
3. Burckhardt CS, Anderson KL, Archenholtz B, Hägg O. The Flanagan Quality Of Life Scale: evidence of construct validity. Health Qual Life Outcomes. 2003 Oct 23;1:59. doi: 10.1186/1477-7525-1-59. PMID: 14613563; PMCID: PMC269996.

4. Ohio State University. "Role of spleen in prolonged anxiety after stress." ScienceDaily. ScienceDaily, 13 November 2016. <[www.sciencedaily.com/releases/2016/11/161113154748.htm](http://www.sciencedaily.com/releases/2016/11/161113154748.htm)>.)
5. Organon of medicine. New Delhi: B. Jain; 2016.
6. Schroyens Synthesis Repertory 9.0 [ English], Radar 10 Software.
7. Boericke W. Boericke's New Manual of Homoeopathic Materia Medica with Repertory. 3rd ed. New Delhi: B. Jain Publishers (P) Ltd.; 2007.
8. Bailey, P.M. (1995) Homeopathic psychology: Personality profiles of the major constitutional remedies. Berkeley, CA: North Atlantic Books.
9. Clarke, J.H. (2000) A dictionary of practical materia medica. Sittingbourne: Homœopathic Book Service.
10. Hughes, R. and Allen, T.F. (2000) The encyclopedia of pure materia medica: A record of the positive effects of drugs upon the healthy human organism. New Delhi: B. Jain.
11. Scholten J. (2008) Homoeopathy and Minerals. Homeopathic Medical Publishers
12. Sankaran R. The soul of remedies. Bombay, India: Homoeopathic Medical Publishers; 1997.
13. Bloor A, Nayak R. Archith Bloor Ramadas Nayak Medicine Exam Preparatory Manual for Undergraduates, 3rd ed, Jaypee Brothers Medical Publishers Pvt. Limited.
14. MUNJAL Y, Sharm S. API Textbook of Medicine, Ninth Edition, Two Volume Set.

**Disclaimer/Publisher's Note:**

The statements, opinions and data contained in all publications are solely those of the individual author(s) and contributor(s) and not of MDPI and/or the editor(s). MDPI and/or the editor(s) disclaim responsibility for any injury to people or property resulting from any ideas, methods, instructions or products referred to in the content.