

Hypothyroidism and Kent's Twelve Observation

Virendra S. Jain M.D (HOM), Dr.Ankita. Thete

Dr. Komal. Jain

A female aged 29 years came on 10 / 01 / 2017 for the homoeopathic treatment of Hypothyroidism with following symptoms.

Presenting Complaints & History of Presenting Complaints –

1. swelling on face and neck (double fold) .since 7-8 yrs.
2. Hyperpigmentation on face, neck, dorsum of hands, axilla, along with pigmented patches on abdomen.
3. Hair fall.
4. Generalized weakness and tiredness.
5. Pain in nape of neck.
6. Pain in thigh > tight bandaging.
7. Headache occipital and frontal ameliorated by tight bandaging around head.

General Symptoms-

Appetite – adequate 3-4 chapatti and rice.

Thirst – 3-4 lit per day.

Desire- indigestible things, rice, bread.

Aversion – sour things, cake.

Stool – satisfactory. Once/ day.

Urine – 5-6 times/ day.

Perspiration – on vertex.

Allergy- NS

Sleep- unrefreshing. Feels sleepy.

Dream- NS.

Menstrual History-

Regular 3/28

Duration- 3 days.

Character of blood- profuse black clotted.

Pain in lumbar region during flow.

Personal History-

Patient by occupation is a student of BHMS belonging to middle class socio-economic family.

Past History-

In 2006 she was admitted in KEM hospital for swelling of face. Fainting attack. Her irritability was increased. When she was admitted, Neurologist said that there was a tumor in pituitary gland by seeing contrast MRI reports. Later on she had done some blood test but the reports were normal. So she was discharged from hospital. After that she decided to take homoeopathic treatment in May 2016.

Family History-

Mother- Apparently Healthy.

Father- Died.

Brother- Apparently Healthy.

PRESENT MEDICATION

Thyronorm 150 mg.

On Examination-

Face- puffy, swelled, oedematous.

Neck- oedematous with double folds. Dark pigmentation over neck

Conjunctiva- Pink

Sclera- white

Nails- Pink

Extremities- Thin

Abdomen- Pot belly

Eyelids- swollen

Thermal – Hot.

Mentals-

She had done Diploma in Pharmacy later she joined graduation. She was unsuccessful in her first attempt and then the complaints started and there after she always had fear during and after exams... She does not like company because she thinks people will observe her and question her which she didn't like. She kept herself away from social company because of it. She has selective friends. She said she is having intolerance to external noises.

Investigation – Submitted reports before treatment-

Patient's report Normal Range

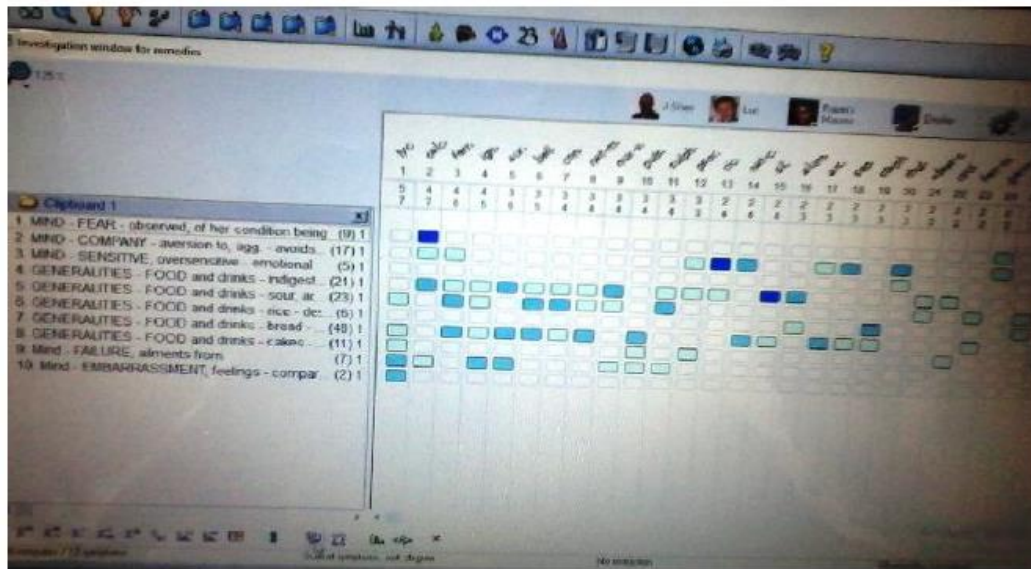
T3- 88.27 ng/dl 0.20 – 1.81

T4- 9.14 ul/dl 4.80 – 11.3

TSH – 10.11 ulu/dl 0.35 – 5.50

Diagnosis- Hypothyroidism

Case was repertorised on the following symptoms by using RADAR 10.5 (Complete Repertory) is shown in Table.



First Prescription – Lycopodium 1M- 1 Dose.

Phytum 30 – 20 days.

Basis of Prescription –

DATE	SYMPTOMS	MEDICINE	DOSE
5 /2/ 2017	Swelling decreased Hair fall decreased	Phytum # Thyronorm 150 mg	For 25 days / 4 pills TDS
1 /3 / 2017	Overall improvement	Phytum #Thyronorm 100 mg	For 25 days / 4 pills TDS
29 / 3 / 2017	General improvement	Phytum # Thyronorm 75 mg	For 25 days / 4 pills TDS
26 /4/ 2017	Overall improvement 25 / 4 / 2017 T3- 0.16 ng/ml T4- 1.87 ul/dl TSH- 91.98 ulu/ml	Phytum # Thyronorm 50 mg	For 25 days / 4 pills TDS
20 / 5/ 2017	Overall improvement	Phytum # Thyronorm 25 mg	For 25 days / 4 pills TDS
17 / 6 / 2017	Overall improvement 16 /6 /2017 T3- 1.20 ng/ml T4- 8.08 ul/dl TSH- 3.33 ulu/dl	Phytum	For 25 days / 4 pills TDS

In repertorisation Lyco, Calc Carb, Ign, Aurum were coming in leading score. In this case, Lycopodium was selected as the ailments from in this case is failure (in examination), Embarrassment feeling – company. Which led to physical complaints. In subsequent follow ups the patient responded well. On the other hand though Calc and Ign were coming in repertorisation but they were not matching the intensity of mental symptoms of the patient.

Result

After giving Lycopodium 1M, she started feeling better, pigmentation decreased, swelling decreased. Overall felt better. Confidence increased. Jan 2017 – July 2017 was her course of homoeopathic treatment. And now on todays date she is absolutely fine. In due course of treatment all her physical complaints disappeared. In first TFT during course of treatment where dose of Thyronorm was reduced by 50 mg. Later in successive follow ups with regular check ups / TFT the Thyronorm is tapered gradually. Presently her dose of Thyronorm is completely stopped. Till today she is kept on Placebo and regular assessment of her TFT which shows Thyronormalcy.

Follow Ups

Follow ups are still going on with regular assessment of TFT allopathic medication stopped completely since 1 month and is continued on Placebo.

Discussion

Homoeopathic literature mentions many medicine for the condition of which a similimum can help a patient keeping the disease at bay for a longer period as evidenced in this case. Homoeopathic medicine offers gentle and safe relief and reduces chances of recurrence significantly. Patient has highest satisfaction after taking the treatment. She is married now, happy in her daily routine, feels better about her looks. In relation to **Kent's 12 observations** , as per **4th observation** **“NO AGGRAVATION WITH RECOVERY OF THE PATIENT.”**

Inference

Remedy and potency-exactly correct.

No organic disease or no tendency to organic disease.

The disease is not of great depth and belongs to the function of nerves.

Prognosis

Good (Not to disturb the action of the medicine.)

Conclusion

Homoeopathy take care of chronic problems in an individual, where in Allopathic or conventional medicine advices Hormone Replacement Therapy. However, the results from this single case report are conclusive regarding the long term clinical effectiveness of Homoeopathy for Hypothyroidism.