

A Case of Haemorrhoids Treated With Magnesium Carb - A Retrospective, Observational Study

Dr Smitha Nair, Dr Vasudha Bagul, Kritika Mishra, Sangeetha Pillai, Tasneem Siddiqui, Lakshmi Shaji, Sonali Padwale, Avanish Gupta.

Abstract

A female patient presented with the complaints of bright red bleeding from rectum, lump in anus, constipation since childhood, she had not taken any treatment before. Considering the totality of symptoms, Magnesium Carb 200 was prescribed which proved effective and resulted general improvement and relief was observed from first follow up which is Kent's 4th observation.

Keywords

Homoeopathy, Hemorrhoids, Constipation, Magnesium Carb, Kent's 4th observation.

Introduction-

Hemorrhoids are enlarged veins located in the lower part of the rectum and the anus. External hemorrhoids originate below the dentate line, while internal hemorrhoids are above the line and are classified according to their degree of prolapse from the anal canal. ^[1]

Grades of Hemorrhoids

Grade I - Visualized by anoscopy, there is bulge into the lumen but do not extend below the dentate line,

Grade II- prolapse out of the anal canal with defecation or with straining but reduce spontaneously

Grade III - prolapse out of the anal canal with defecation or straining, and require reduction,

Grade IV - are irreducible and may strangulate. ^{[2][3]}

It is important to differentiate a hemorrhoids from other growths like anal papillae or polyps. Polyps are usually asymptomatic but occasionally grow large enough to be felt by the patient or are likely to prolapse. Hypertrophied anal papilla, composed of a smooth mass located near the anal verge, is also considered a differential diagnosis especially in a patient with a history of chronic anal irritation or infection. ^[4]

About 75% of people have hemorrhoids at some point in their lives ^[5]. Hemorrhoids is most common among adults aged 45-65. ^[6]

About 80% of people in India develop hemorrhoids and about 80% aged over 50 have some form of symptomatic hemorrhoidal disease.

Over three-quarters of individuals in the United States have hemorrhoids at some point in their lives, and about half of the population over age of 50 requires treatment ^[10]

Some common symptoms include bleeding from the rectum, anal itching, general discomfort and an

external anal protrusion. Patients who are suffering from this condition should be treated quickly and monitored carefully in order to prevent the development of infections associated with the condition for which homoeopathy is effective.^[7]

Surgical procedures like haemorrhoidectomy open method, closed method, stapler haemorrhoidectomy, Doppler guided hemorrhoidal artery ligation are available but some severe complications can occur.^[10]

Septic complications following both conservative and surgical treatment of hemorrhoids are rare but may be catastrophic.^[8]

Globally, over 600 million people use homoeopathy as a system of medicine to treat ailments. Of this, about 100 million are Indians and by 2017.^[11]

Under classical Homeopathic treatment, hemorrhoid patients improve considerably in their symptoms severity.^[9]

DR JAMES TYLER KENT's 4th observation is- No aggravation with recovery of the patient which indicates correct remedy and potency.^[12]

Case Report

A 21 yrs. old female presented with bleeding per rectum, swelling & lump at anal region which protrudes during stool, burning pain during stool, constipation tendency to get pimples and diarrhoea during menses.

Patient is suffering from constipation since childhood and dysmenorrhoea since menarche. Based on mental, emotional and physical make up Magnesium carb 200 was prescribed. Past history- history of tuberculosis (at the age of 3 months), Typhoid at the age of 18 years Family history of Hemorrhoids (Father) & Rheumatoid arthritis (Mother)

Personal history

The patient was vegetarian with average built. She drinks less quantity of water (2-3 glasses/day), constipated with hard stools, loves to eat chocolates, offensive and perspiration staining Lenin yellow, perspires all over the body, tendency to pimples and Loose stool during menses and Get rash from exposure to lawn grass.

The patient did not have good relations with her mother. Mother was excessively dominating. She wanted to have a good affectionate relation with her mother.

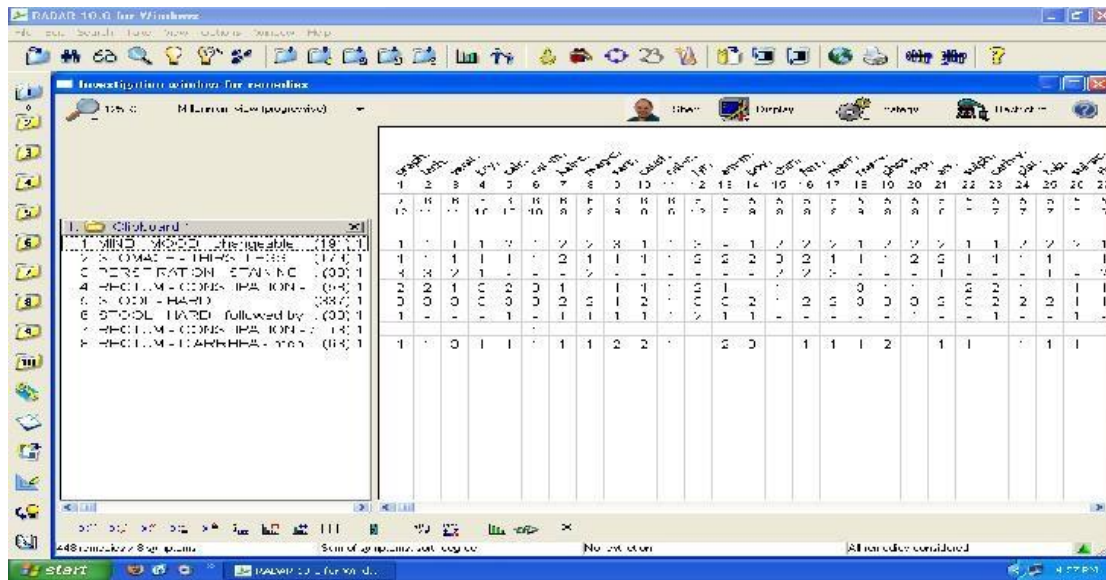
She had mood swings, her family members used to talk about her marriage which she hated.

Examination:-

Proctoscopy revealed cherry red mass, seen inside lumen Following symptoms were considered in reportorial totality-

1. Mirilli's theme-mother.
2. Changeable mood.
3. Thirst less.
4. Perspiration staining yellow chronic constipation.

5. Soft stool followed by hard stool.
6. Constipation with hemorrhoids.
7. Diarrhoea during menses.



Prescription-after case taking and Repertorisation, single dose of Magnesium Carb 200 was prescribed on the day of visit along with placebo to be taken 3 times a day for 10 days

Follow ups After 10 days in the 1st follow up patient reported mental peace, fresh feeling. Constipation was relieved, stool were satisfactory. Bleeding was less than before, thirst was

Discussion

In this case of hemorrhoids Magnesium carb was prescribed on the basis of totality of symptom. On first follow up after ten days patient reported general feeling of wellbeing, bleeding per rectum reduced though the patient cannot be termed as to be cured this is definitely a way to improvement according to Herring's law of cure, which states that cure take place from within outwards, from more important to less important organs thus this case highlights the Dr Kents's 4th observation, which suggests that the disease is limited to its functional level, remedy and potency selection was correct, there is amelioration without aggravation. Here physician has to wait and watch.

Reference-

1. Parker GS. A new treatment option for grades III and IV hemorrhoids supplement to. J FAM Pract 2004; 800
2. Banov L Jr, knoepp LF Jr, Erdman LH, Alia RT. Management of haemorrhoidal disease. J S C Med Assoc 1985; 81:398-401 pubmed
For Prolapse and H
3. Parker GS, Mindy E. W Procedure hemorrhoids: A New Approach to a Gynecologic Dilemma; Supplement to OBG management; August 2005; S3-7.
4. Gupta PJ. Hypertrophied anal papillae and fibrous anal polyps, should they be removed during

- anal fissure surgery? World J Gastroenterology 2004; 10:2412-5. Pubmed
6. Baker H. Hemorrhoids. In: Longe JL, editor. Gale Encyclopedia of Medicine. 3rd ed. Detroit: Gale; 2006. p. 1766-9.
6. Chong PS, Bartolo DC. Hemorrhoids and fissure in ano. Gastroenterol Clin of North Am 2008;37:627-44, ix
7. Padmalaya Rath, Harleen Kaur, A case of haemorrhoids in a 12-year-old boy IJRH, 29 MAR 2014
8. R.J.Guy, F.Seow-choen, Septic complications after treatment of haemorrhoids, British journal of surgery, first published: 22 November 2002
DOI: 10.1002/bjs.4008
9. Kaushik Deb Das, Shubhamoy Ghosh, Asim Kumar Das, Alok Ghosh, Ramkumar Mondal, Tanapa Banergee, Seikh Swaif Ali, Munmun Koley, Subhranil Saha- Treatment of hemorrhoids with individualized homeopathy: An open observational pilot study, Journal of Intercultural Ethnopharmacology 2016sep-dec, 335-342,
10. Douglas J. MacKay, ND Candidate, 2001, Hemorrhoids and Varicose Veins: A Review of Treatment Options, Alternative Medicine Review, Volume 6, and Number 2, 2001
11. Business standard reporter, Homoeopathy market set to double by 2017 Bengaluru April 8, 2015
Last Updated at 20:40 IST
12. Dr James Tyler Kent,