

Efficacy of Morgan Pure a Bowel Nosode as an Intercurrent remedy in treating Tinea Corporis in the age group of 5 to 50 years: A Case Series

Rutika Sonawane, Vaibhavee Bheda, Dinesh Tayade, Dr. G.B. Prasad, Dr. Manisha Ahiwalay, Dr. Varsha Dharne, Dr. Ashwini Aher, Dr. Asha Bhosale, Dr. Natasha Dewani, Dr. F.F. Motiwala,

Abstract

Background: Tinea corporis is no longer fungal infection but rather most stubborn clinical condition. Tinea corporis is common superficial infection of skin caused by dermatophytes. Tinea corporis is usually flat, itchy, circular rash with clearer skin in middle initially, later with raised border spreading radially with erythematous vesicular edges. It may expand with irregular circles giving this infection a layman terminology Ringworm. **Aim and Objective:** This study was aimed to see the efficacy of Morgan Pure a bowel nosode, as an Intercurrent remedy in treating Tinea Corporis in the age group of 5 to 50 years, and to improve the quality of life of patients. **Materials and methods:** Fourty five cases were selected based on inclusion criteria. The improvement in Quality of life, using Dermatological life quality index (DLQI) scale was studied before and after the treatment. **Result:** Significant improvement in DLQI was observed and verified using paired t test. **Conclusion:** The study has explored the potential of using Morgan pure, that can be used as an intercurrent in cases of Tinea corporis infection, which not only improved skin complaints but also the quality of life of the patients.

Key words- Bowel nosode, DLQI scale, Homoeopathy, Intercurrent remedy, Morgan Pure, Tinea Corporis

Introduction:

Tinea corporis (Ringworm) is no longer fungal infection but rather most stubborn clinical condition. Tinea corporis is common superficial infection of skin caused by dermatophytes. Prevalence of Tinea corporis is 20-25% world wide, and in India it is most common in tropical region. ⁽¹⁾Males are more commonly affected than females, the ratio being 1.67:1.00.⁽²⁾ Dermatophytes is commonly related fungi that invade keratinized tissue of human and animals to cause infection known as dermatophytosis referred as “Ringworm” due to appearance of lesion of tinea. ⁽¹⁾ Tinea corporis is usually flat, itchy, circular rash with clearer skin in middle initially later with raised border spreading radially with erythematous vesicular edges. It may expand with irregular circles giving this infection a layman terminology Ringworm.⁽³⁾ It has become difficult to treat, with increasing number of failure of treatment. The lesion may become widespread and may have negative social, psychological and occupational health effect and compromise the quality of life. The treatment of Tinea corporis is based on the constitution of the individual. These constitutional Homoeopathic remedies sometimes do not relieve the patient or do not progress after a certain time. Intercurrent remedies are used to complete the curative process in chronic disease. Even after treatment with well selected medicine, if the patients do not show progress, a Nosode acts as an intercurrent remedy. When in some chronic cases after a period, patient condition refuses to progress, this condition can be termed as blockage. To remove this blockage, an intercurrent remedy can be used ⁽¹²⁾. The nosodes are to be remembered in this condition. A single dose of the appropriate nosode in a moderately high potency, will sometimes clear up a case. According to Stuart close, “Intercurrent remedies are the remedies which serve to arouse the organism to reaction so that indicated remedies will act.”⁽¹³⁾

Morgan Pure is a type of bowel nosode. Morgan pure has remarkable indication on skin

infection, with variable results.⁽⁵⁾ This study has attempted to show the efficacy of the Morgan pure as an intercurrent remedy in treating Tinea corporis cases. Thereby to improve the quality of life of patient. The study was conducted at Motiwala (National) Homoeopathic Medical College and Hospital, Nashik.

Materials and method:

A prospective study was carried out in out-patient Department of Motiwala (National) Homoeopathic Medical College, Nashik. Ethical clearance was obtained from Institutional ethics committee. Patients considered were assessed on the basis of DLQI scale and indicated homoeopathic medicine were prescribed at the entry of the cases under study. The patients who did not show any improvement with the well selected individualized homoeopathic medicine were given Morgan pure as an intercurrent remedy in subsequent follow up on the basis of score obtained by applying clinical assessment of Tinea Corporis infection scale.

Patients in the age group 5-50 years and both the genders. Patient who are willing to be the part of study and patients with no complication of lichenification pathology have been enrolled in the study. Patients with diagnosed immune-suppressive diseases and who are clinically diagnosed with psoriasis, lichen planus, eczema, and other bacterial and viral diseases of skin are excluded from the study.

A total number of 45 patients aged from 5 to 50 years according inclusion and exclusion criteria from Motiwala (National) homoeopathic medical college OPD and peripheral medical camp, who complained of recurrent Tinea corporis infection were considered into the study. Informed consent were taken and specific case record format was filled and status of improvement was assessed through the Dermatological life quality index (DLQI) scale. The questionnaire comprises of questions pertaining to quality of life in physical, psychological, social and environmental domains. Improvement of DLQI was calculated based on comparison of score at the time of enrollment and at the end of the study period.

Each individual patient was prescribed indicated homoeopathic medicine based on symptom similarity and repertorization. Follow up were taken at the interval of 15 days or early if required. Based on clinical assesment score morgan pure was prescribed on subsequent follow up.

DLQI scale ,questionnaire with ten questions on quality of life was filled by the patients at the beginning of treatment and end of study. The patients improvement is assessed by score arrived as per the study methodology.

Results :

1. Mean DLQI score was 15.33 before treatment and 6.91 after treatment, it was difference; mean was compared using paired t test the calculated t was 13.66 Table value of t at 5% level of significance is 2.02 which is much lesser than thecalculated t value. Hence we can say that we reject the null hypothesis.

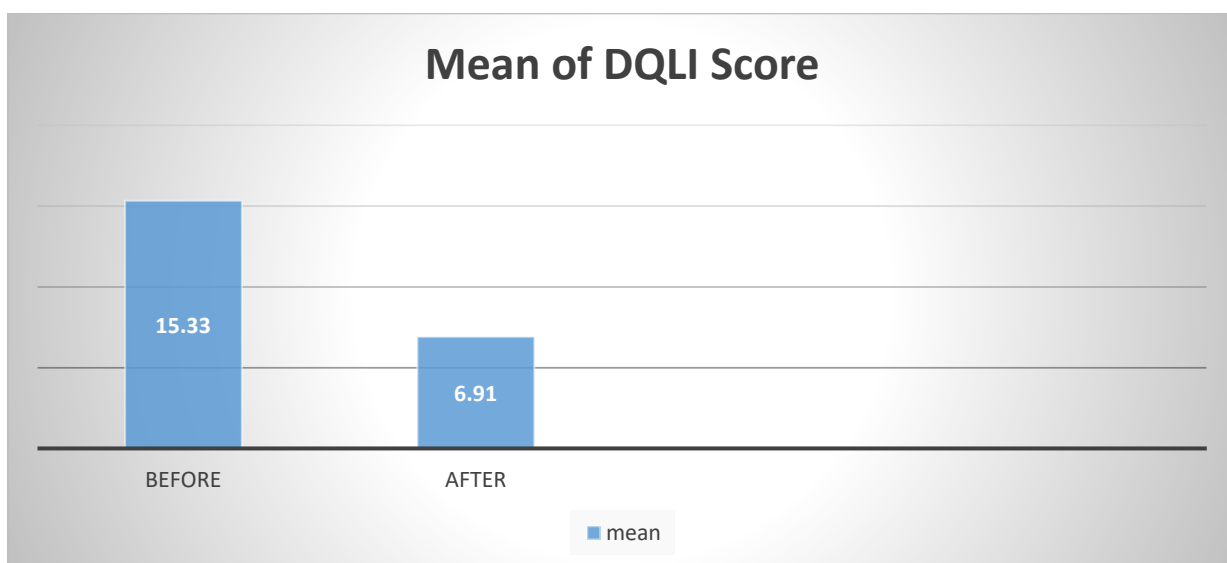


Fig no. 1 Graphical Representation of mean of DQLI score

2. Incidence of TineaCorporis on Male and Female out of 45 patients 27 male patients (60%) and 18 female patients (40%) were observed in the study.

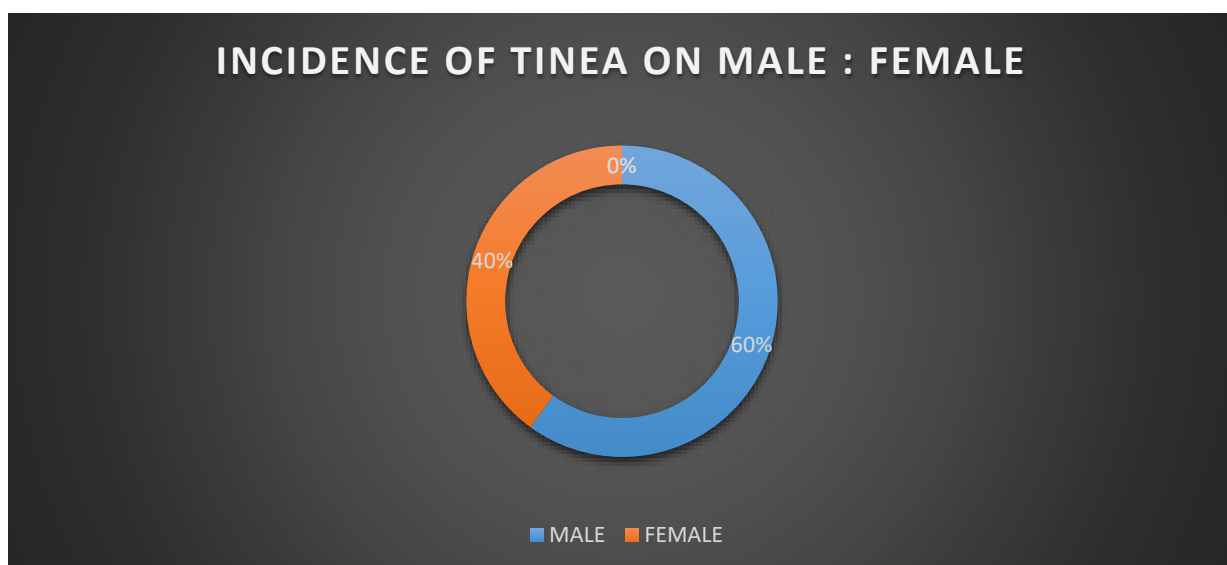


Fig no 2. Incidence of Tinea Male: Female

Discussion :

Tinea corporis is no longer just a fungal infection but rather most stubborn clinical condition. Most commonly affected area includes legs, groins, scalp and under the breast. tinea infection is transmitted indirectly through skin contact or through towels, clothings etc. It is superficial infection of skin caused by dermatophytes. It is flat, circular with severe itching and spread in irregular circles. With increasing in failure of treatment, along with negative social, psychological impact attempt to improve the quality of life of patient was aimed.

The study assessed the effect of Tineacorporis on 45 patients aged from 5 to 50 years according inclusion and exclusion criteria from Motiwala (National) homoeopathic medical

college OPD and peripheral camp, who complained of recurrent Tinea corporis infection. The status of improvement was assessed through the Dermatological life quality index (DLQI) scale.

Out of 45 patients, 2 patient had Extremely severe effect, 39 patient very severe effect and 4 patients moderate effect on their daily routine due to Tinea Corporis infection before treatment. They were given indicated homoeopathic medicine on basis of symptom similarity and initial DLQI score was taken. On subsequent 1,2,3 follow up bowel nosode Morgan Pure 200, single dose along with Sac lac for 15days was given to patient. Follow ups were taken after every 15 days, and 6 such follow up were taken. In all cases morgan pure was required as intercurrent remedy; this shows us that the morgan pure may be required as intercurrent remedy in all cases of Tinea Corporis infection.

At the end of 6th Follow up it was observed that no patient had extremely severe effect on their daily routine. 8 patients had still very large effect, 19 patient had moderate effect, 16 patient had small effect and 2 patients had no effect of tinea corporis on their daily routine and Final DLQI score was taken into consideration. All the patient showed improvement in their sign and symptoms. The interpretation is depicted in tabulation and graphical format.

Conclusion :

The study shows that Morgan pure is effective as an intercurrent remedy in Tinea Corporis patients aged from 5 to 50 years. Hence, Morgan pure can be used as an intercurrent in cases of Tinea Corporis, which not only improved skin complaints but helped in regulating female menstrual cycle.

Reference :

1. NagaralGV, Veerabhadra GoudGK, SudhaP. Jagadevi. Prevalence of tinea corporis and tinea cruris in Chitradurga rural population. IP Indian J ClinExpDermatol.2018;4(3):2215.
2. Balamuruganvelu S, Reddy SV, Babu G. Age and Genderwise Seasonal Distribution of Dermatophytosis in a Tertiary Care Hospital, Puducherry, India. Journal of Clinical & Diagnostic Research. 2019 Feb 1; 13(2).
3. Practice of dermatology by PN Behl, A Aggarwal GovindSrivastav 10th edition chapter 12 page no. 167
4. <https://www.cardiff.ac.uk/medicine/resources/quality-of-life-questionnaires/dermatology-life-quality-indexDQLISCALE> REFERENCE.
5. Keynotes and characteristics with comparisons of some of the leading remedies of the Materia medica with bowel nosodes. H.C.Allen.
6. Woo, Taylor E. MSc; Somayaji, Ranjani MD; Haber, R. M. MD; Parsons, Laurie MD. Diagnosis and Management of Cutaneous Tinea Infections. Advances in Skin & Wound Care 32(8):p 350-357, August 2019. |DOI:10.1097/01.ASW.0000569128.44287.67
7. <https://www.mayoclinic.org/diseases-conditions/ringworm-body/symptoms-causes/syc-20353780>
8. Gupta, Seema and P Jain. "Role of homoeopathic medicines in

- tineacorporis: A casestudy.”(2019).
9. Materiamedicafbowel nosodes withtherapeutic indicationbyGupta.
 10. Sharma CP, Ambwani M, Saraswat K. Bowel nosodes-a boon tohomoeopathy.<https://baksonhmc.com/wp-content/uploads/2022/08/Bowel-nosode-a-boon-to-homoeopathy-By-Dr.-C.P-Sharma-Dr.-Meenakshi-Ambwani-Dr.-Kruti-Saraswat.pdf>
 11. Gupta Y, Tuteja S, Acharya A, Tripathi V. Effectiveness of Homoeopathy in TineacorporisandTineacruris– AProspective,LongitudinalObservationalStudy.InternationalJournal of Advanced
 12. Ayurveda, Yoga, Unani, Siddhaand Homeopathy 2021 Mar 12; 10(1): 61827
 13. Close Stuart. The Genius of homoeopathy lectures and essays on homoeopathicphilosophy. B. JainPublishers (P) Ltd; Chapter13
 14. Organonof medicine6thedition.