

Effectiveness of Natrum muriaticum in treatment of gall stones -a case report**Dr. G.B.Prasad****Abstract**

A female patient aged 58 years, came with a USG report with multiple gall stones. She suffered an episode of pain abdomen in right Hypochondriac region. Her family physician suggested USG of Abdomen, which revealed multiple gall stones with echogenic changes in gall bladder of the patient. The author treated the patient on the basis of symptom similarity of the case to the Homoeopathic Individualized medicine, Natrum muriaticum. During follow Up of the case it was seen conclusively that the Homoeopathic remedy Natrum muriaticum is effective in reducing the number of gall stones.

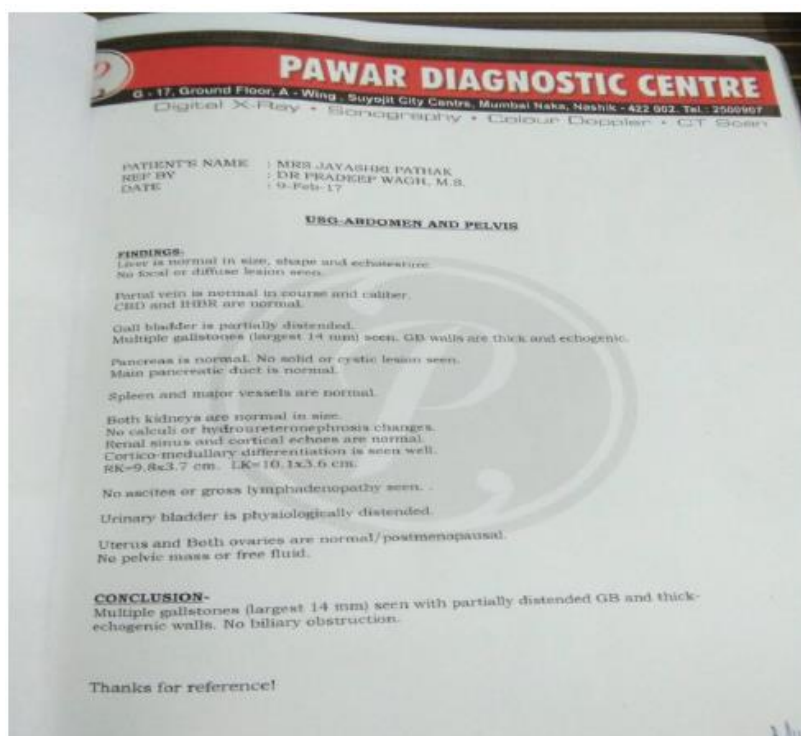
Keywords: Gall stones, Ultrasonography, Natrum muriaticum.

A female patient, Mrs JP, aged 58 years, suffered with an episode of pain abdomen 8 days prior to consultation. Pain was severe aching type in right hypochondrium region <sitting and > by lying down. Her family physician suggested USG of Abdomen, which revealed multiple gall Stones. To avoid surgery she came for Homeopathic treatment. On enquiry about her state of health before the episode of pain abdomen she said that she used to suffer from acidity since 8 years, which is aggravated by shortness of sleep and when she eats toordal. She is also suffering from Headache, one sided either right or left since 8 years. The pain is throbbing type, associated with acidity. She takes tab. Migranil for her headache. Appetite is decreased, Thirsty. No specific desires and aversions. She is constipated with insufficient stools. Perspiration scanty and sleep is short with wakefulness. She is a mild and cheerful lady, who is sensitive to rudeness and criticism. She doesn't want to bother others with her problems. She is hypertensive and is on anti hypertensive drugs. She had suffered from left sided sciatica in the past (revealed during follow up). On further enquiry she told that her husband expired about 8 years back. He was a railway employee and was a loving person. She said: "we used to travel a lot together". She has a son who got into railways after her husband's death while in service. Her son left home and was staying separately with his wife. She somehow managed to convince her son, and daughter-in-law, who are now staying with her. According to her: her Husband's death left her alone and helpless. She expressed the fear of recurrence of pain.

Examination:

Tenderness in right hypochondrium. Murphy's sign Positive. B.P: 140/80 mm of Hg.

Investigation: conclusion of USG report is, multiple gall stones (largest 14mm) seen with partially distended gall bladder and thick echogenic walls. No biliary obstruction.



Repertorial Totality:

1. MIND - AILMENTS FROM – mortification
2. MIND - FORSAKEN feeling
3. MIND – MILDNESS
4. MIND - FEAR - pain - of the pain
5. MIND - REVERENCE for those around him
6. MIND - SENSITIVE - rudeness, to
7. STOMACH – THIRSTLESS
8. RECTUM - CONSTIPATION – insufficient
9. SLEEP - SHORT
10. ABDOMEN - PAIN - Hypochondria – right

me (201)

Jayashree Pathak 12/297 - Cholelithiasis

This analysis contains 370 remedies and 10 symptoms.

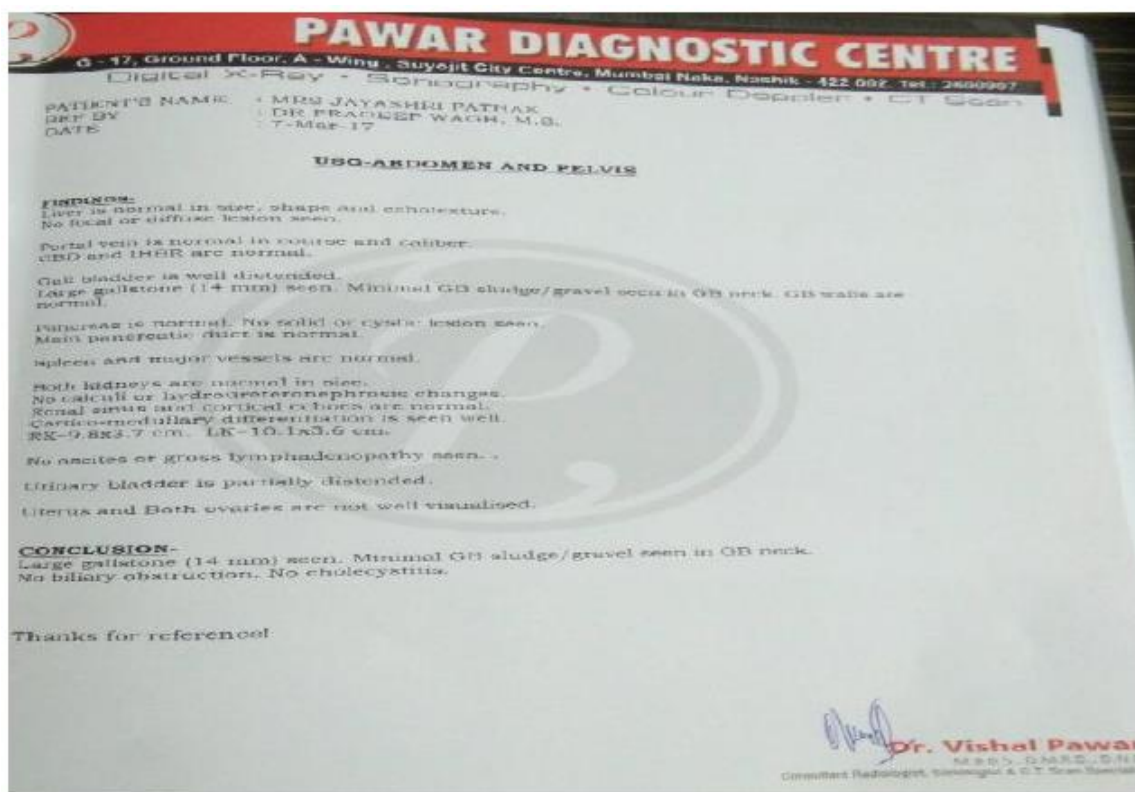
Intensity is considered

Sum of symptoms (sort:deg)	nat-m. nux-v. calc. lyc. phos. sep. puls. staph. ph-ac. sulph. ars. bry. nat-c. podo. rhus-t. aur. kail-c. stram. thuj. mag-m.																				
	1	2	3	4	5	6	7	8	9	10	11	12	13	14	15	16	17	18	19	20	
01. MIND - AILMENTS FROM - mortification	1	64	3	2	1	3	1	1	2	4	3	2	1	2	-	1	1	2	-	1	-
02. MIND - FORSAKEN feeling	1	114	2	-	1	-	-	1	3	-	-	-	-	-	2	1	1	3	1	2	2
03. MIND - MILDNESS	1	106	3	2	2	2	2	2	3	1	1	2	3	-	1	1	3	1	1	2	2
04. MIND - FEAR - pain - of the pain	1	14	-	-	1	1	1	-	-	-	-	-	1	-	-	1	-	-	-	-	-
05. MIND - REVERENCE for those around him	1	12	1	1	-	-	-	-	1	-	-	-	1	-	-	1	-	-	-	-	-
06. MIND - SENSITIVE - rudeness, to	1	17	1	1	2	-	-	-	1	3	1	-	-	-	-	-	-	-	-	-	1
07. STOMACH - THIRSTLESS	1	169	1	1	1	2	1	2	3	2	3	1	2	1	1	-	2	1	2	2	1
08. RECTUM - CONSTIPATION - insufficient	1	115	3	3	1	2	2	2	-	2	1	3	1	2	3	3	-	1	3	1	2
09. SLEEP - SHORT	1	72	-	1	2	1	1	1	-	1	2	-	1	2	1	-	2	-	1	-	1
10. ABDOMEN - PAIN - Hypochondria - right	1	91	2	3	-	3	2	1	-	-	-	2	2	2	2	3	1	-	1	1	2

Considering the Repertorial totality after consultation with Kent's Materia Medica, Natrum Mur 200 one dose of six pills of size 30 was prescribed on 16/02/2017.

Follow up 1: dated 27/02/2017: pain felt on 24/02/2017, intensity less, took Tab Cyclopam. Headache better. No Acidity. Left Sciatica pain- unable to sit knees folded. Bowels regular & Soft. Sac Lac prescribed

Follow Up 2: dated 09/03/2017: Had pain on 7/3/2017, which was of low intensity. No head ache . No acidity. Sciatica pain better. Stools- Insufficient since last 7 days. USG done on 07/03/2017. USG conclusion: Large gall stone (14mm) seen. Minimal GB sludge/gravel seen in GB neck.- Natrum Mur 200, 1 dose followed by Sac Lac for 1month.



Follow Up 3: dated 01/04/2017: H/o severe pain previous day. Tab.Cyclopam did not relieve. Now mild pain continuous < Sitting > Lying down, Headache left sided. Constipation. Natrum Mur 200 prescribed followed by Sac Lac for one week.

Follow Up 4: Dated 02/04/2017: Patient reported to have had pain abdomen and underwent cholecystectomy.

Discussion:

Individualized Homoeopathic Medicine selected on the basis of symptom similarity to the case in discussion relieved the echogenic changes observed in the USG report first mentioned. It also could reduce the number of gall stones and had converted the stones into gravel/sludge, except for the largest gall stone of 14mm size. The Homoeopathic Medicine could improve the general health of the patient by reducing the acidity and constipation. It was also seen effective in reducing the sciatic pain which patient revealed during follow up. At the time of second follow up, as the patient had constipation for preceding seven days. Based on this Physical general symptom Natrum Mur 200 was prescribed. Patient was

reportedly asymptomatic for about three weeks. During third follow up, considering recurrence of pain abdomen and its severity Natrum Mur 200 was prescribed, which could not relieve the pain, she was advised to go for ultrasonography of abdomen. The patient did not report back for further treatment, and is reported to undergo surgery for cholecystectomy.

Conclusion :

From the case under discussion it is evident that the Individualized Homoeopathic Medicine, Natrum Muriaticum when selected and prescribed on the basis of the symptom similarity is effective in reducing the inflammation of gall bladder, and also is effective in reducing the number and size of the gall bladder stones.